

# ANATOMY

---

# Cranial Nerve Columns

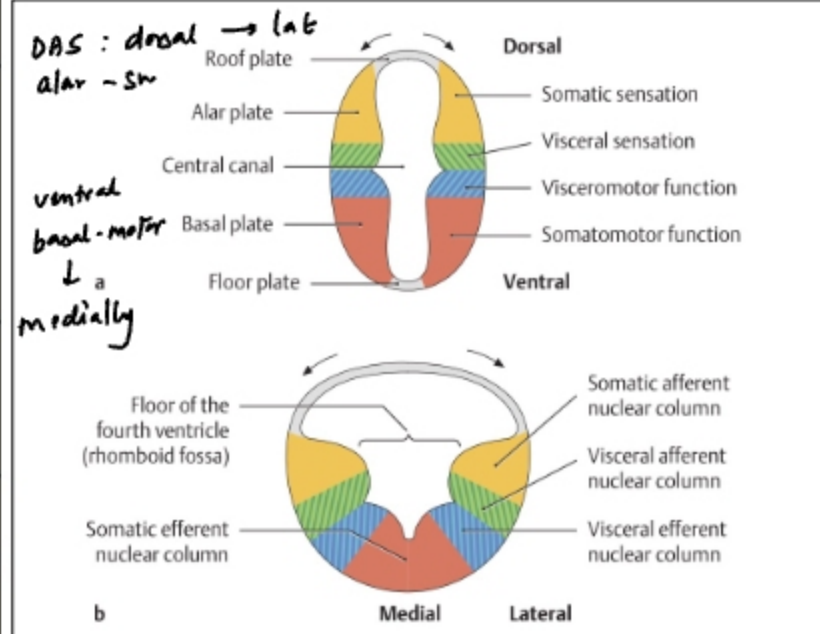
**“SAVE VA SAVE VASE”**

SSA	Ph arches SVE	taste SVA	(Sn) GSA	(Glands) GVE <sup>RR</sup>	viscera - sw baroreceptor GVA	GSE
1	5	—	<u>5</u>	3	—	3
2	7	7	7 } ear	7	7	4 } EDV
8	9	9	9 } ear	9	9	6 } EDV
	10 ↓ Nucleus ambiguus	10	10 } ear	10 ↓ Dorsal motor N	10	12 tongue
		NTS			NTS	11 SCM trapez

Cranial nerve nucleus	Pre-ganglionic	Ganglion	Post-ganglionic	Structure
Edinger-Westphal nucleus	CN III	Ciliary ganglion	Nasociliary nerve Short ciliary nerves (V1)	Ciliary muscles ↓ Miosis → NC
Superior salivatory nucleus	CN VII <sup>GSPN</sup>	Pterygopalatine ganglion → Submandibular ganglion → <sub>CT</sub>	Maxillary nerve (V2) - Zygomatic branch Lingual nerve (V3) →	Lacrimal gland Sublingual/ submandibular glands
Inferior salivatory nucleus	CN IX	Otic ganglion →	Auriculotemporal nerve (V3) (Frey Sx)	Parotid gland
Dorsal motor nucleus	CN X	-	Vagal Nerve	Heart, lungs upper GI (foregut) HR ↓

GSE GVE  
GVA-SVA-GSA-SSA

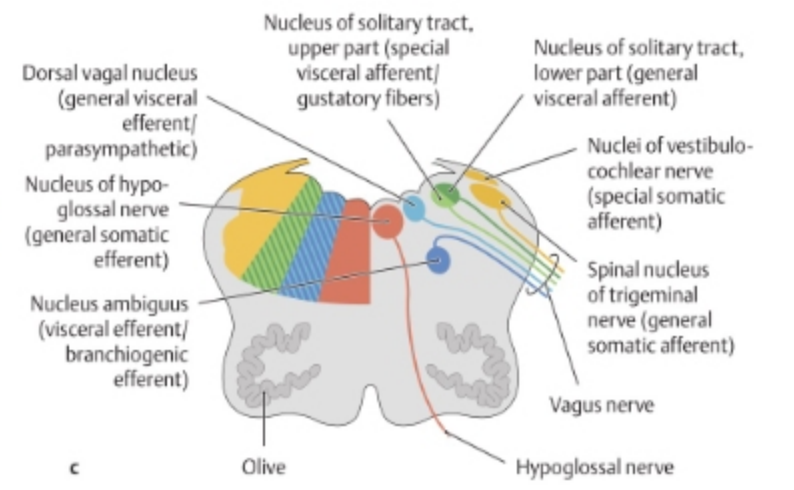
**Medial to lateral:**  
**GSE-SVE-GVE**  
**GVA-SVA-GSA-SSA**



**REFLEXES:**

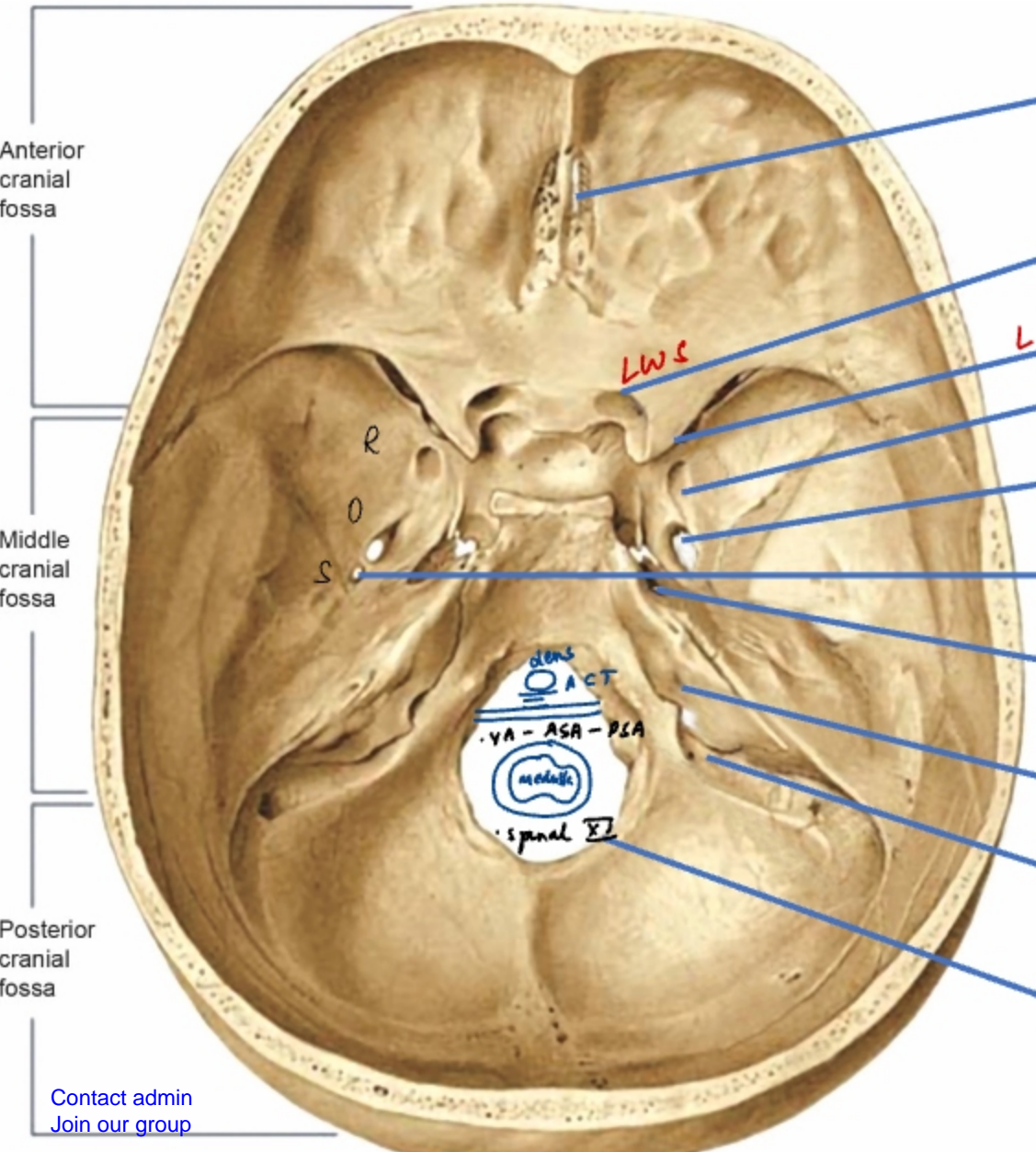
	AFFERENT	EFFERENT
Accommodation	II	III
Pupillary	V1	VII
Corneal		VIII (RLN, ELN)
Lacrimation		IX
Cough	X	X
Gag		X
Jaw jerk	V3	V3

**GSA:** Trigeminal nucleus  
**Mesencephalic:** MB  
**Proprioception** - CNS-only - pseudo-unipolar n  
 Jaw jerk (V3)  
**Principal sensory:** pons  
**Touch, pressure**  
**Spinal:** Pain, temp (medulla)



Contact admin  
Join our group

# Cranial Nerves/ Foramina



Cribiform plate - (I)  
(X) Maxillary

optic canal - II / optm A

SO F - III / IV / VI / V1

LWS - GWS

FR - V2

F. Nale → MA CE

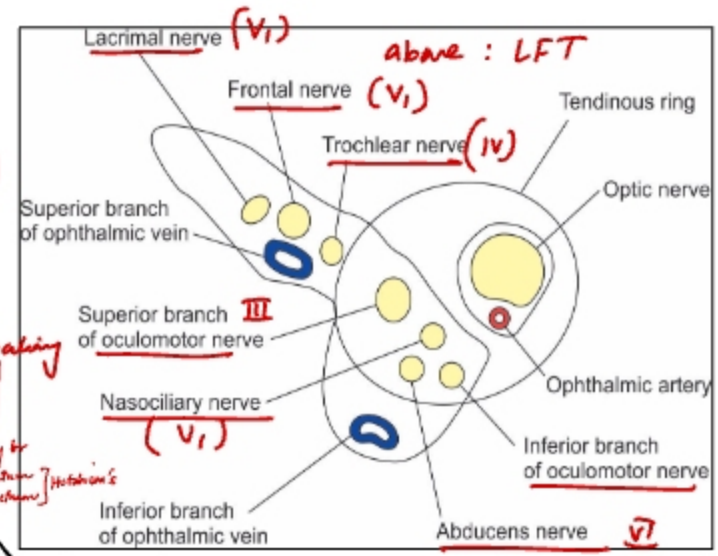
FS → NS + MMA

Foramen lacerum

IAM → 7/8<sup>m</sup>

Jugular forca - 9/10/11

Hypoglossal canal - 12<sup>m</sup>



Lacrimal Frontal Superior branches

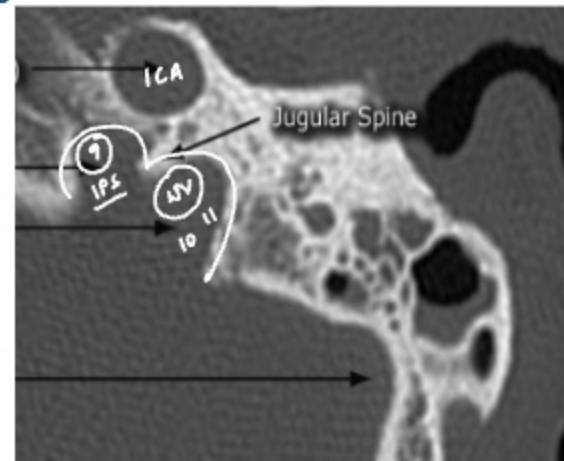
accessory MMA LPN emissary vein

1st part of max A

TOS - sphenoid temp occipital

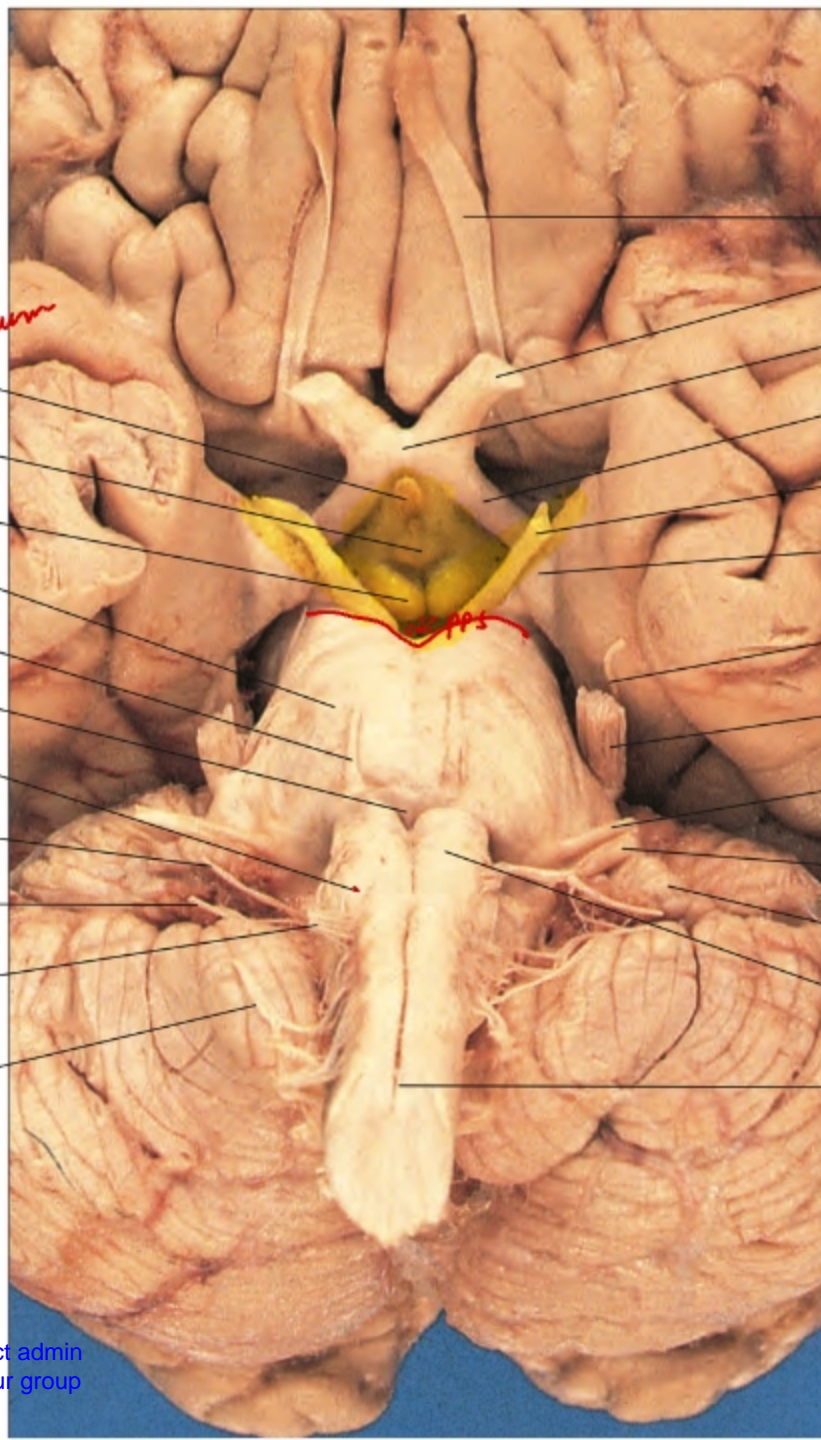
asc pharyngeal A - meningeal br emissary vein over it: ICA / DPN

PN PV

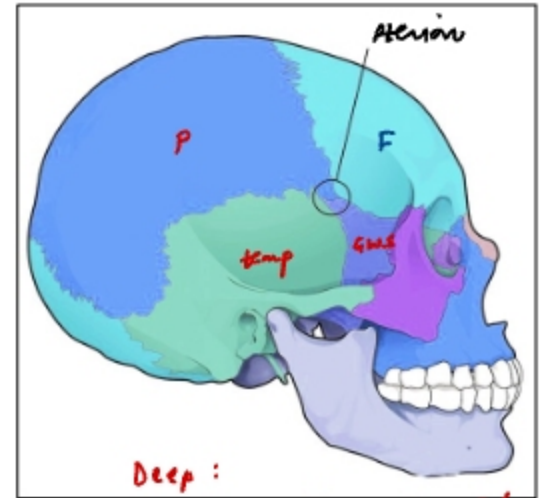
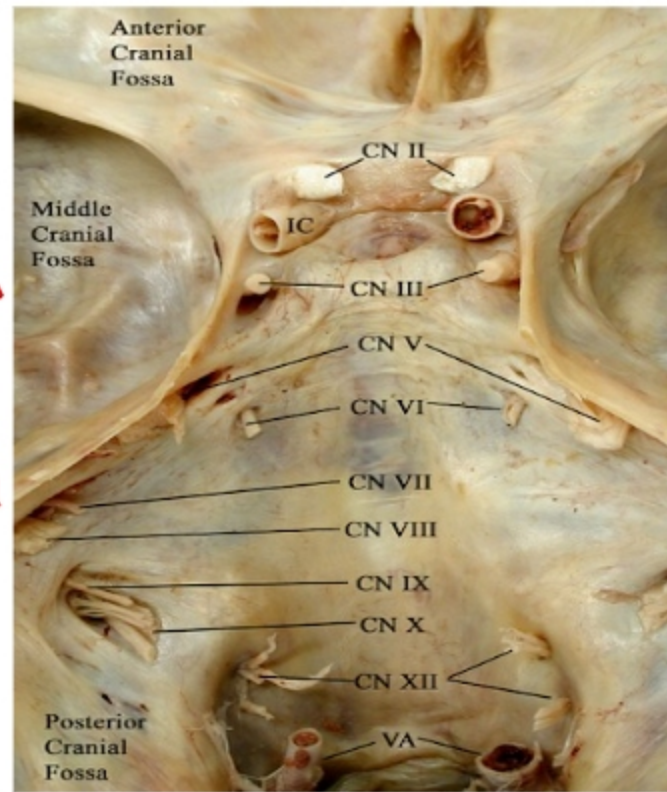
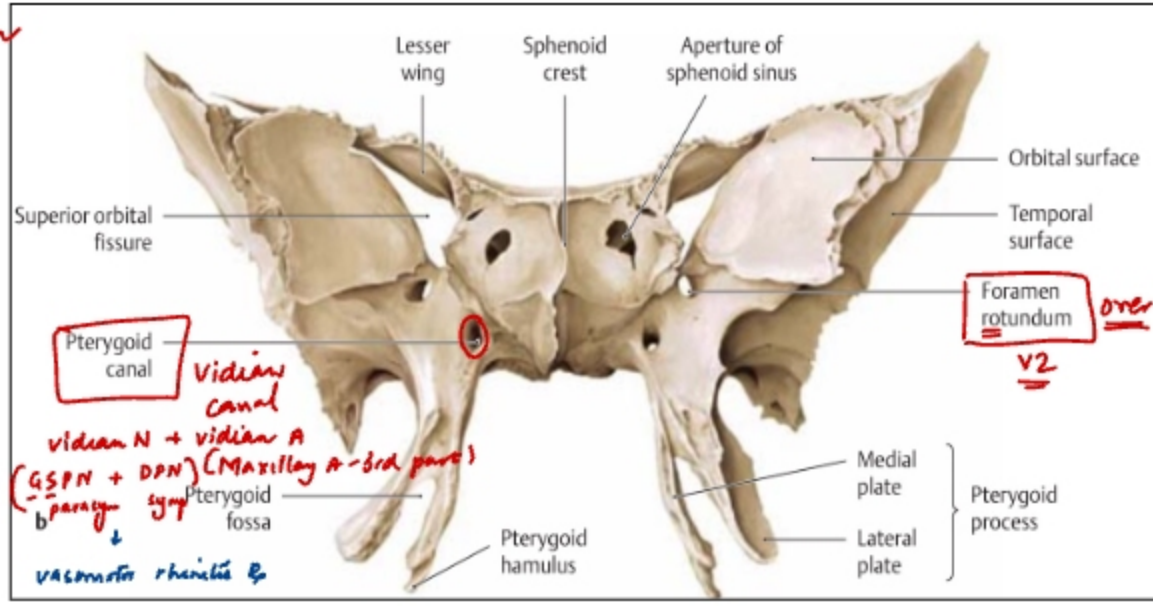


# Ventral - Brainstem

1 Infundibulum  
 2 tuber cinereum  
 3 Mammillary bodies  
 4 PONS  
 5 6th  
 6 For. CEVUM  
 7 olives  
 8 9th  
 9 10th  
 10 12th  
 11 11th



- 12 olf tract
- 13 optic nerve
- 14 chiasma
- 15 tract
- 16 III
- 17 uncus
- 18 IV
- 19 V
- 20 7th
- 21 8th
- 22 flocculus
- 23 pyramid
- 24 decussation of pyramid



- Deep:
- MMA → ant ÷ → EDH
  - Lesser wing of sphenoid
  - Lat colicula - stem
  - Sylvian fissure - MCA
  - Insular CX
  - Broca's area

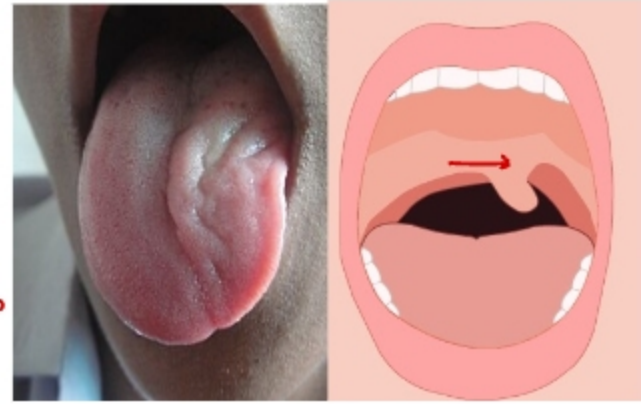
**Dorsal origin**  
**Internal decussation**  
**Longest intracranial course**  
**Thinnest, smallest**

] IV<sup>th</sup>  
 Longest intradural course (Dorello's) → VI<sup>th</sup>  
 Longest intraosseous course (Fallopian) → VII<sup>th</sup>

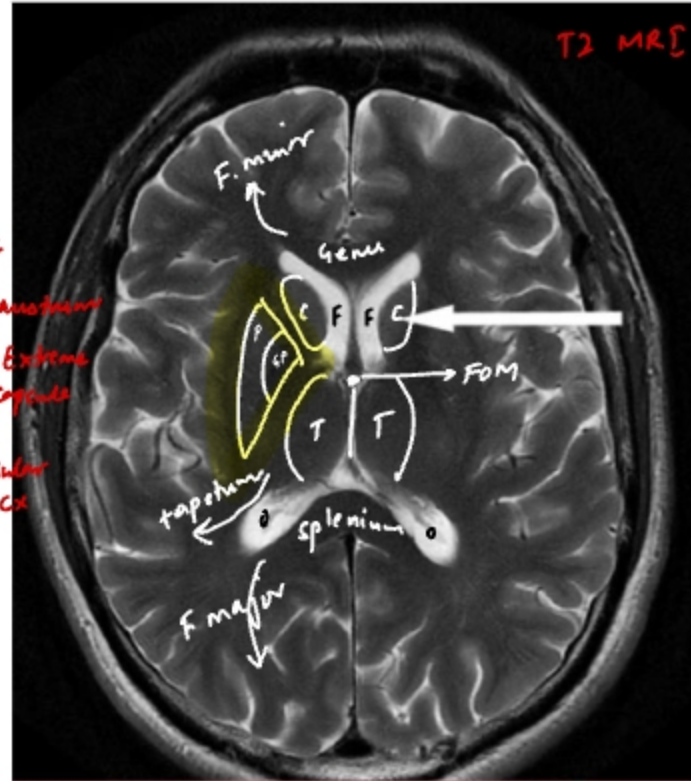
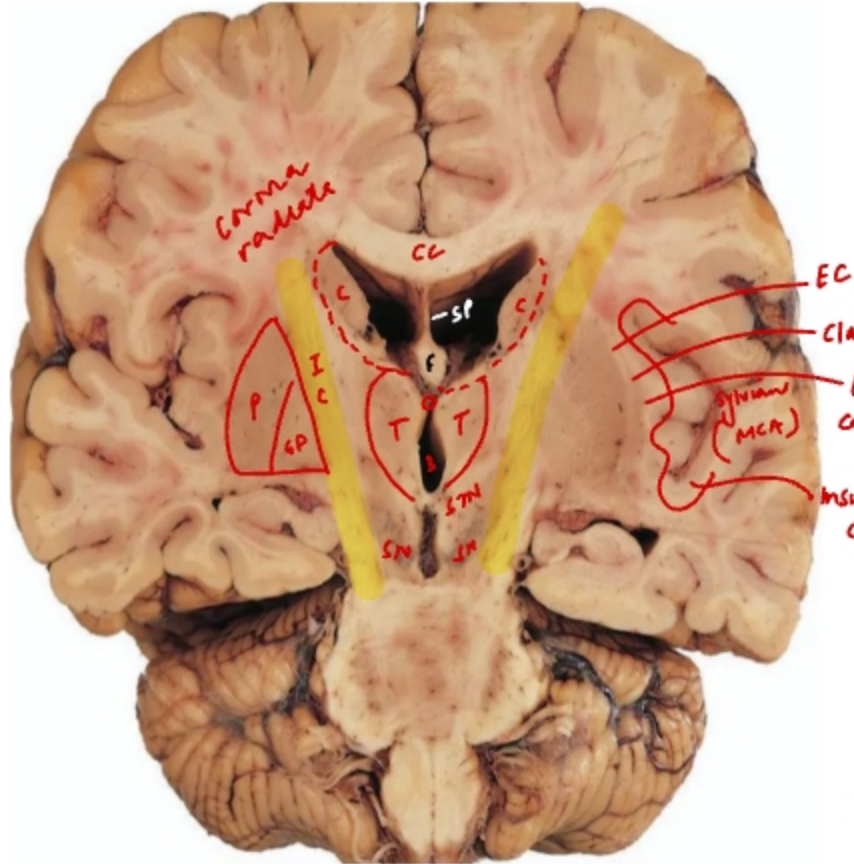
**RULE OF 17:**

10 / 7  
 uvula / jaw  
 c/l deviation

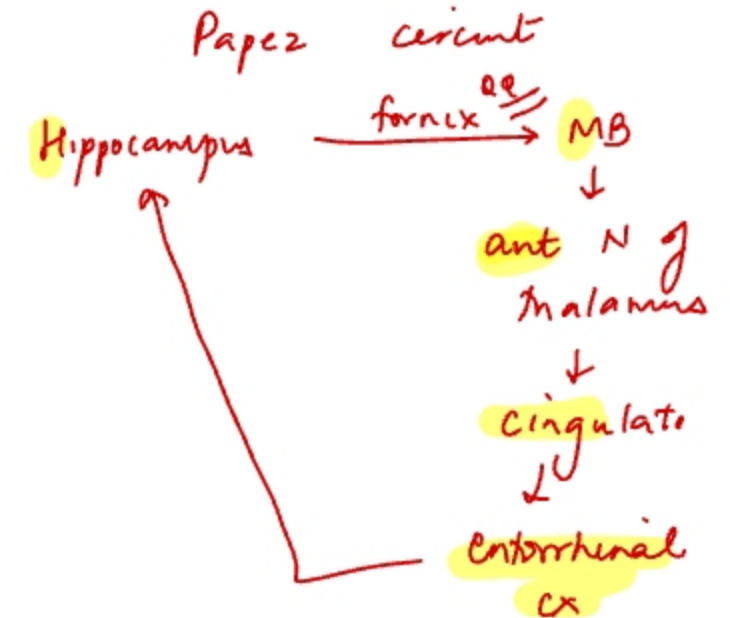
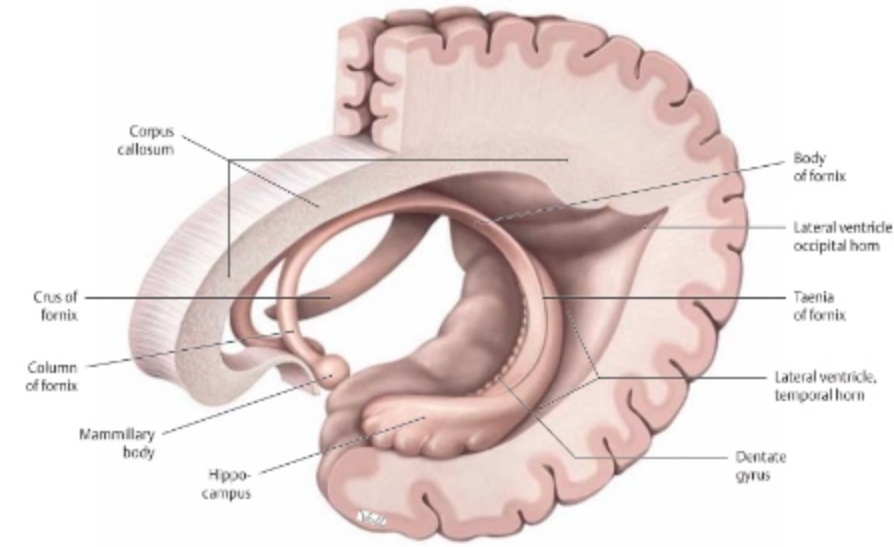
12 / 5  
 tongue / angle  
 i/l deviation

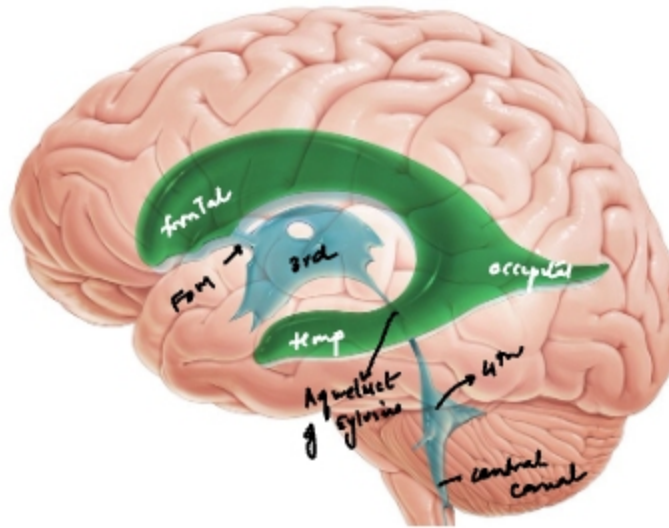
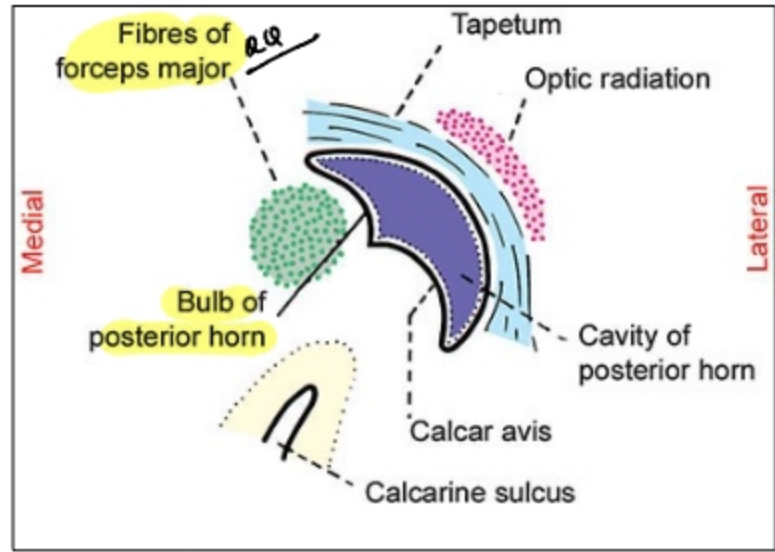
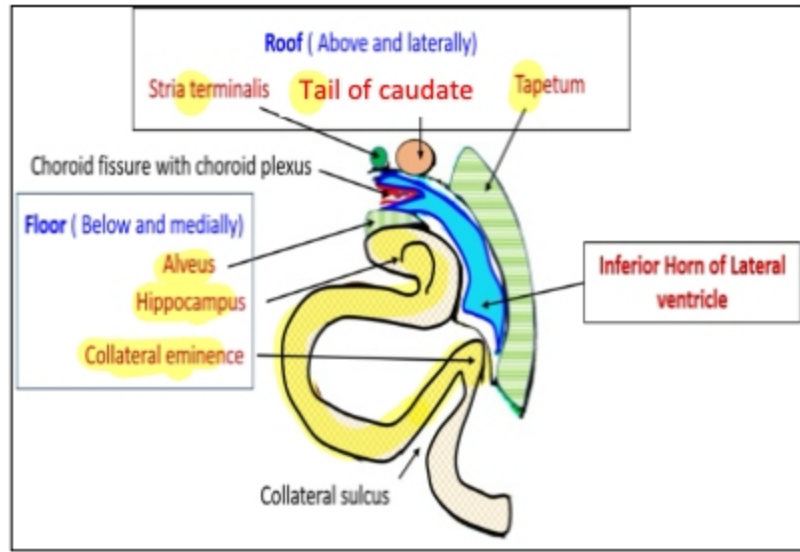
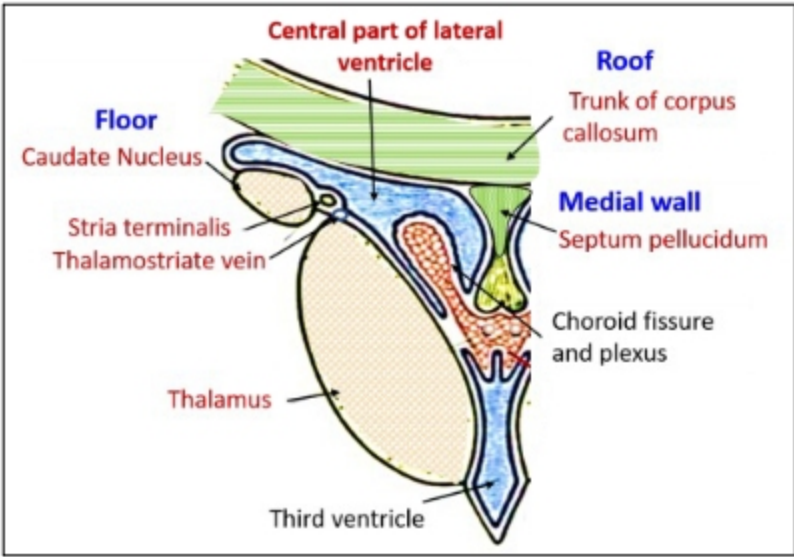


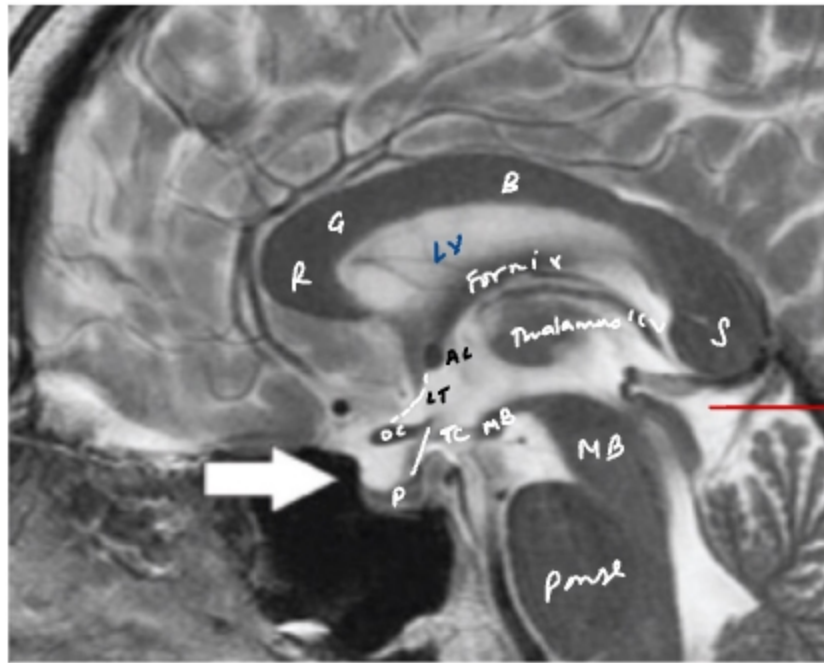
# Neuroanatomy



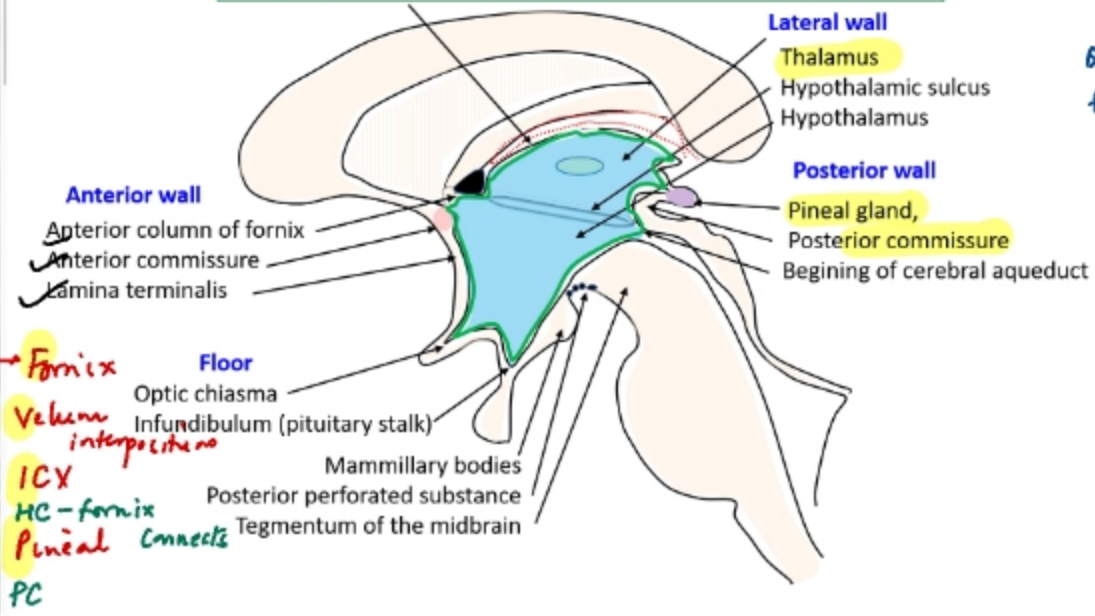
L = GP + Putamen  
Striatum = Caudate + Putamen



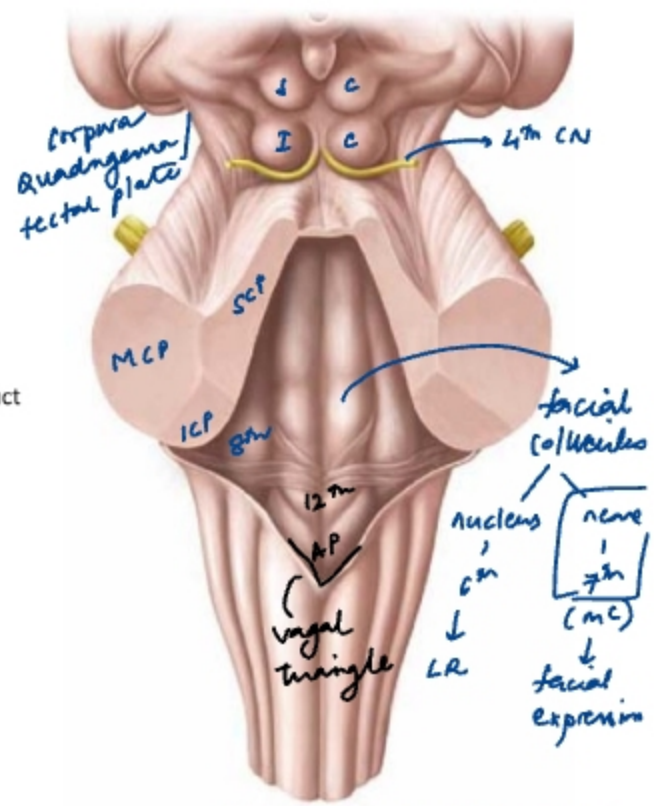




Roof **ependyma** that stretches across the upper limits of two thalami.



**Fornix**  
**Velum interpositum**  
**ICX**  
**HC - fornix**  
**Pineal connects**  
**PC**

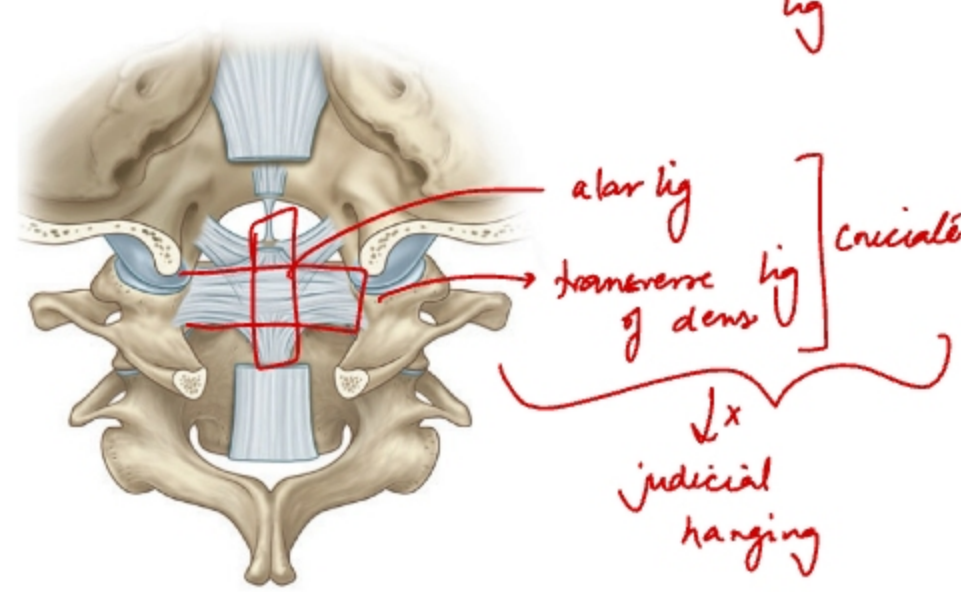
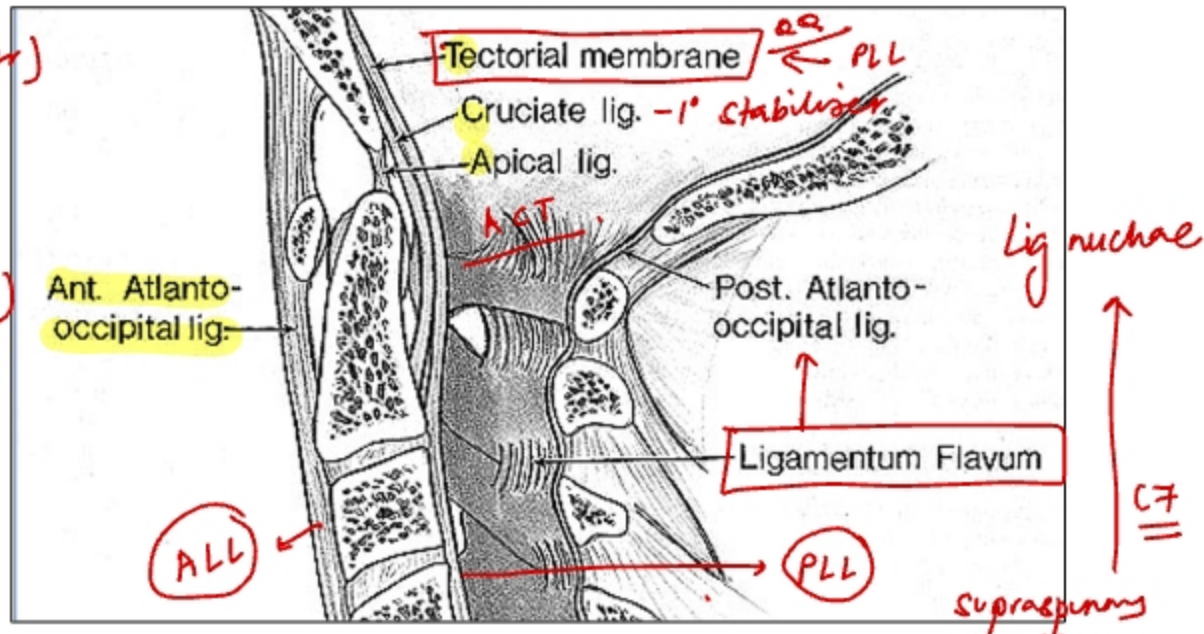
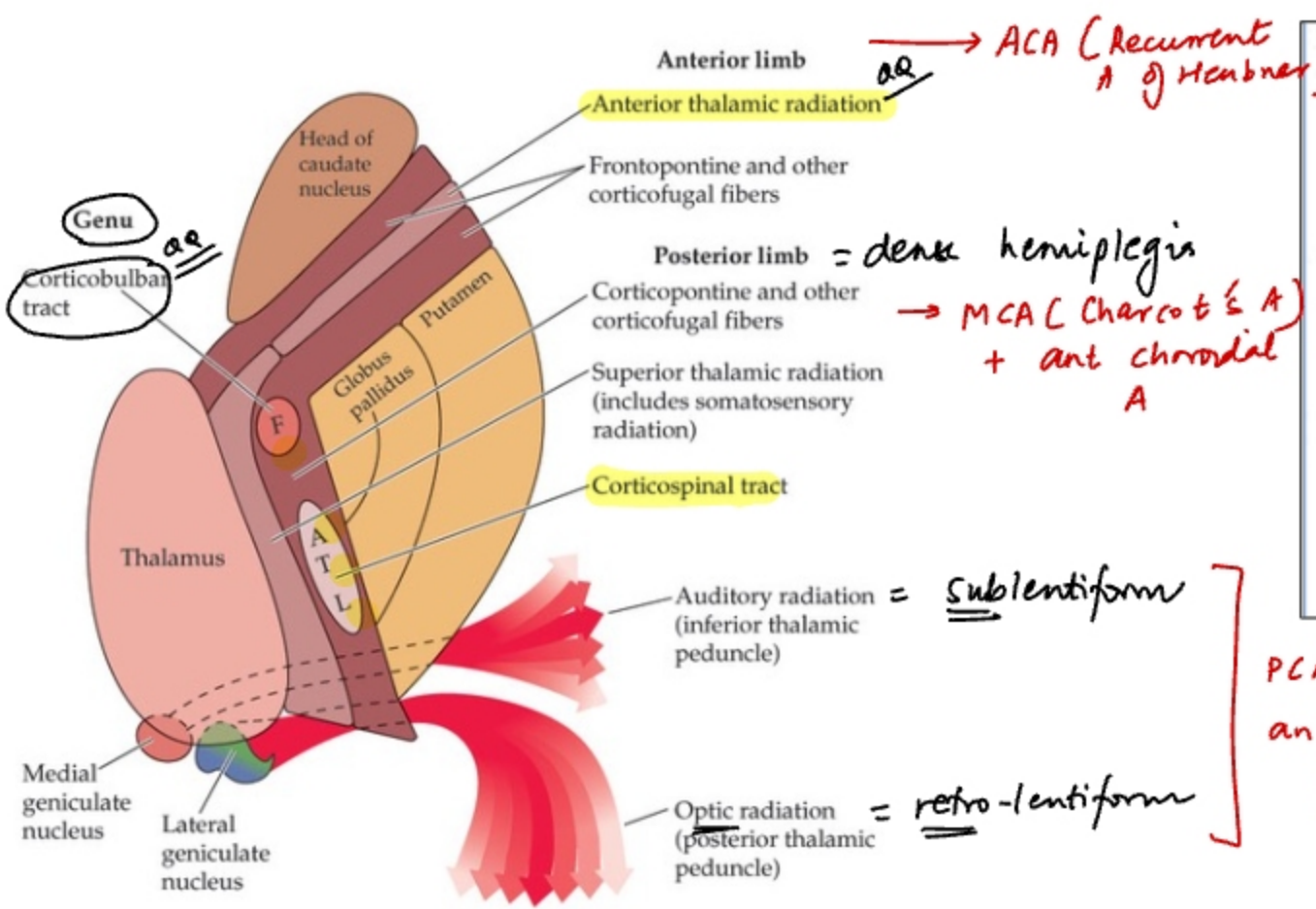


Floor of 4th ventricle / dorsal-brainstem

Lamina terminalis  
 BBB x  
 cranial end of neuroepithelium closes

# White matter tracts

# Cranio-vertebral junction

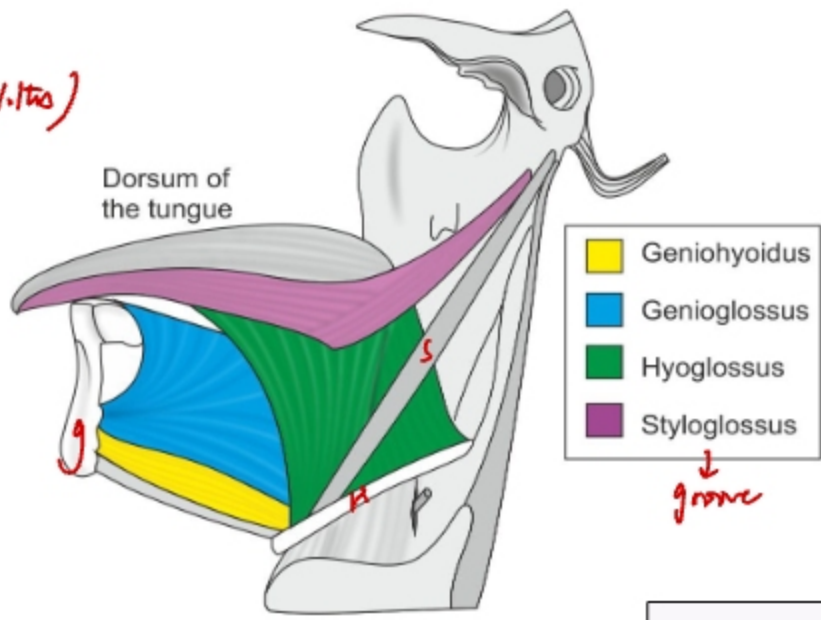
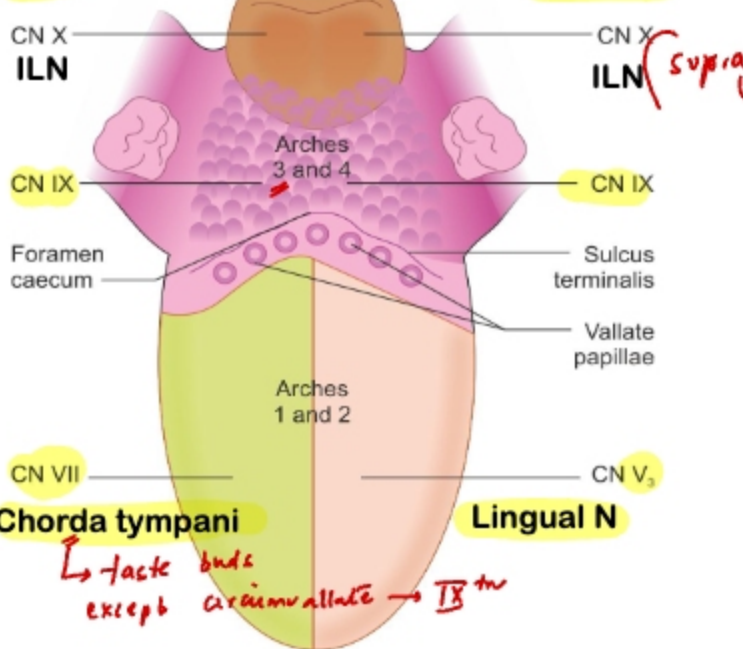


**COMMISURAL:** R-L - Corpus callosum / AC / PC / HC  
**ASSOCIATION:** same side - Arcuate fasciculus / sup-inf long fasciculus / cingulum  
**PROJECTION:** C-S tract, C-B tract - int capsule  
**FORNIX:** A > C > P (all)

Contact admin  
JRC group

# Tongue and floor of mouth

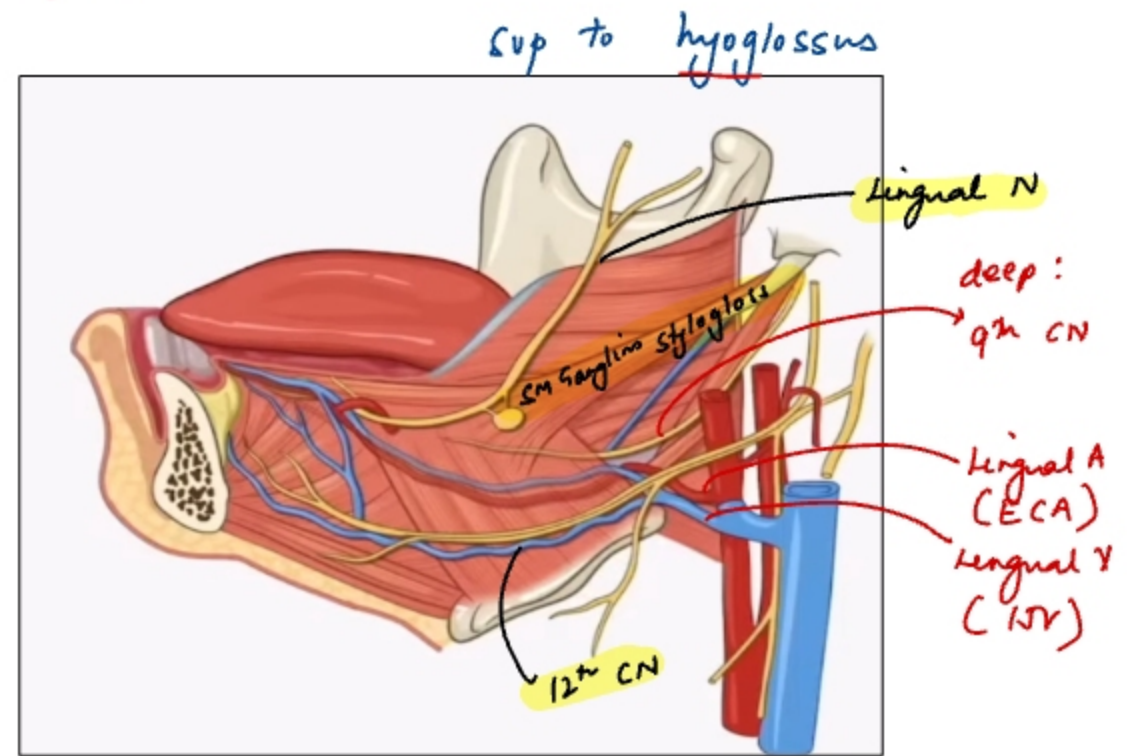
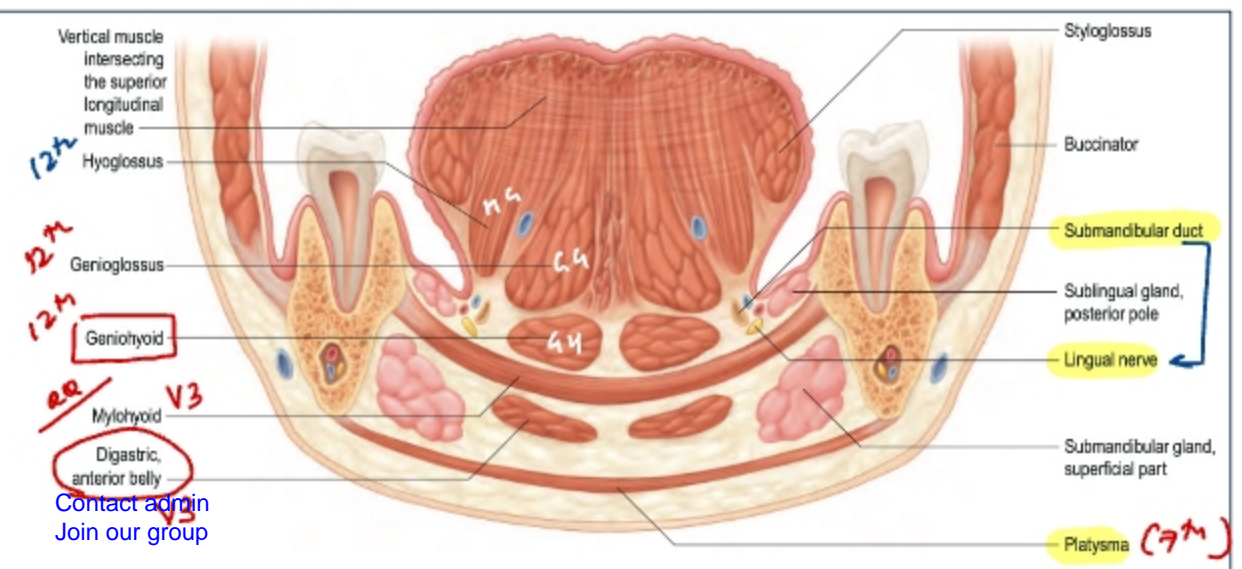
**Taste**      **Sensation**



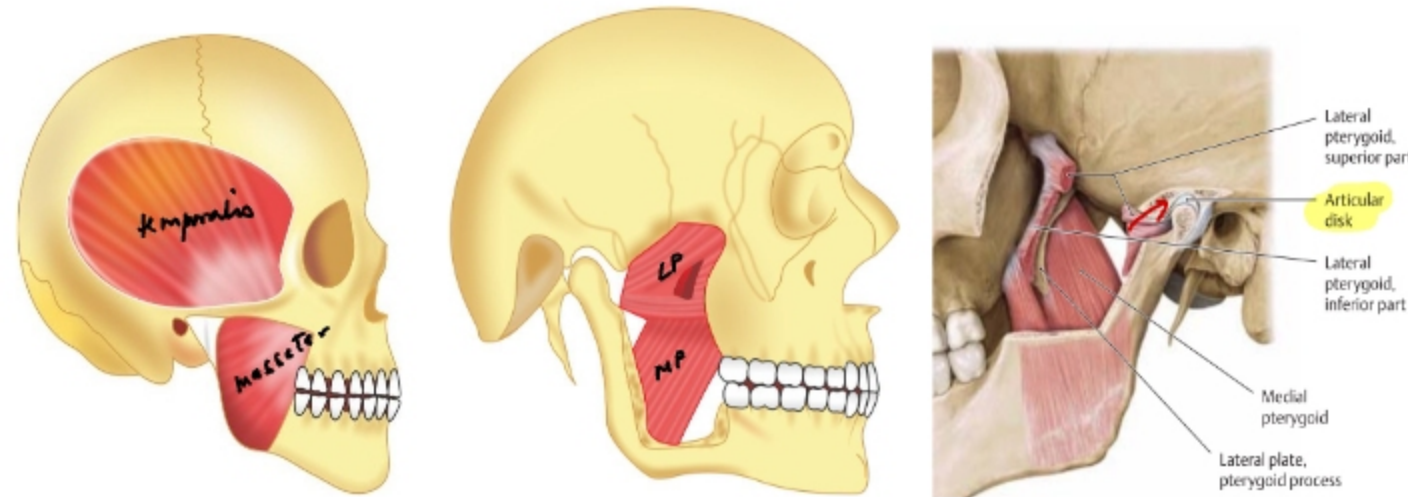
All muscles supplied by except 12<sup>th</sup> CN (occipital myotomes) (palatoglossus) (SLN (EBN))

Safety muscle: Genioglossus (∴ protruder)

Depressor: Hyoglossus



# Muscles of mastication



All muscles supplied by  $V_3$  except MP (main trunk  $V_3$ ) (ant div)

All elevators except LP lowers

All protractors except temporalis retracts  
Main protractor: LP

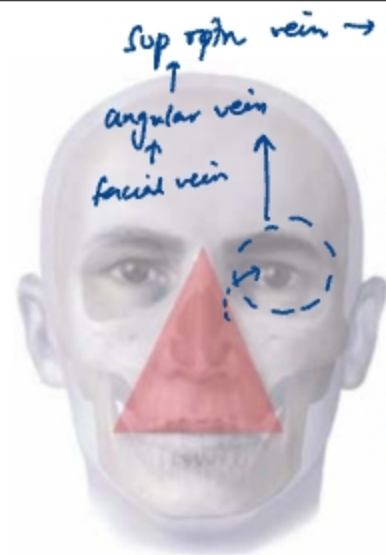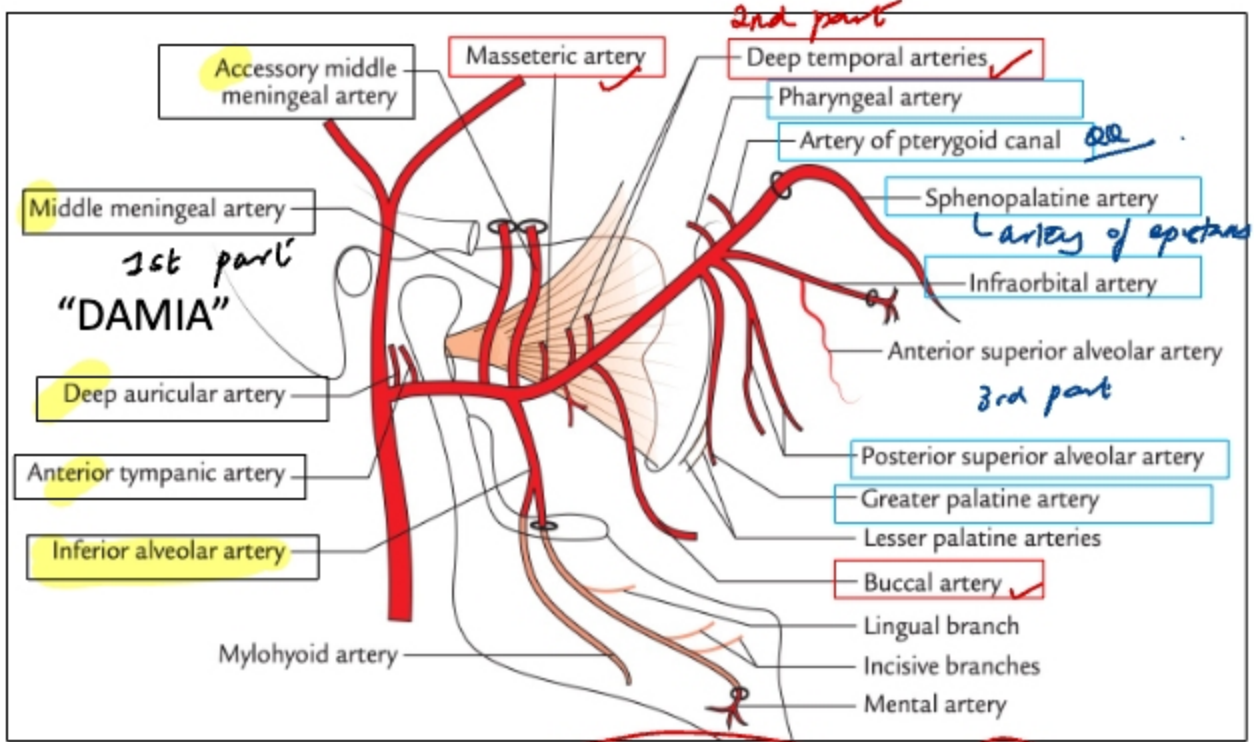
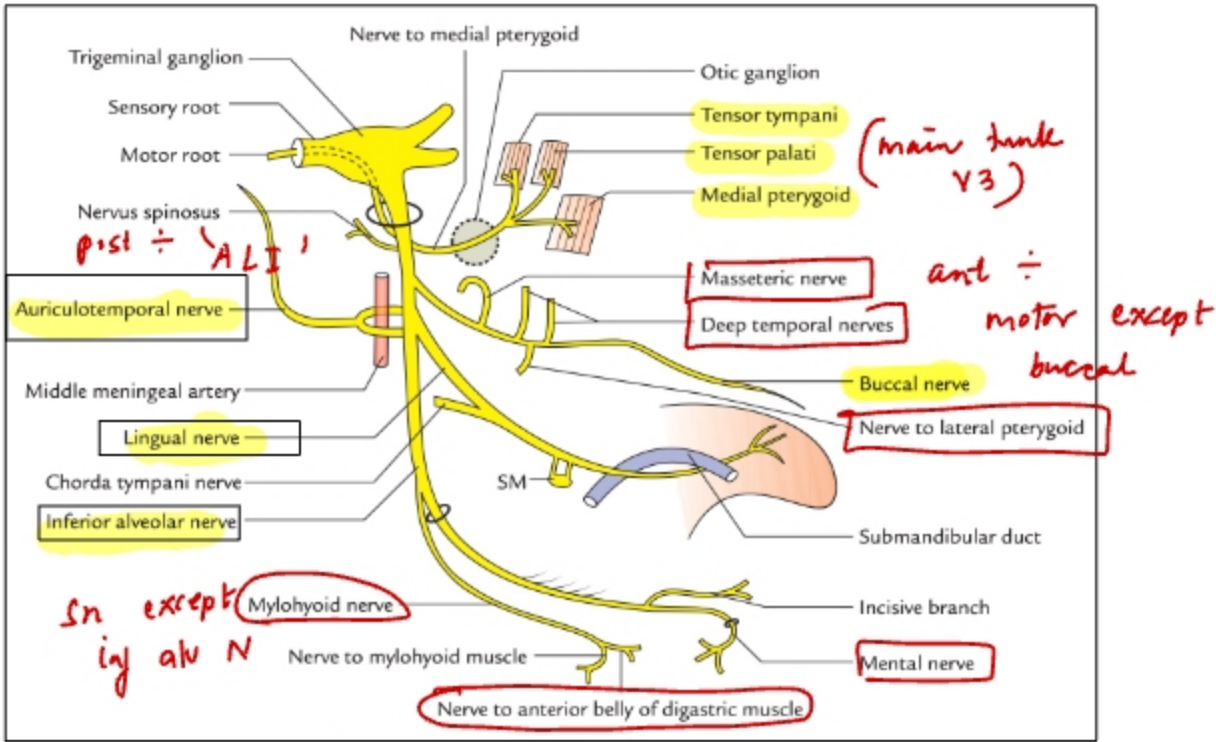
Attached to articular disc of TMJ: LP

Lock jaw: Medial pterygoid  
~~Lock jaw while yawning: LP~~

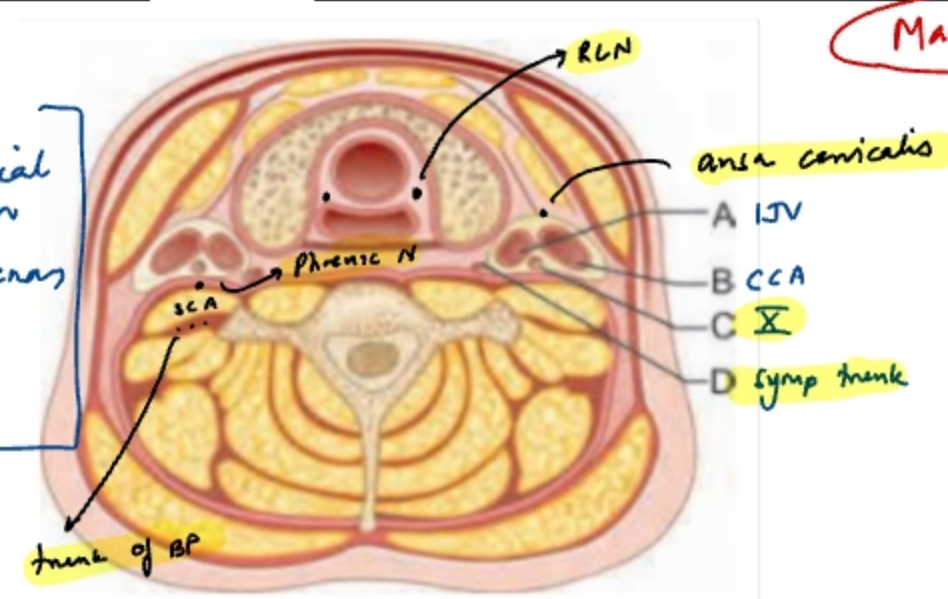
Accessory masticator muscle: Buccinator (VII)

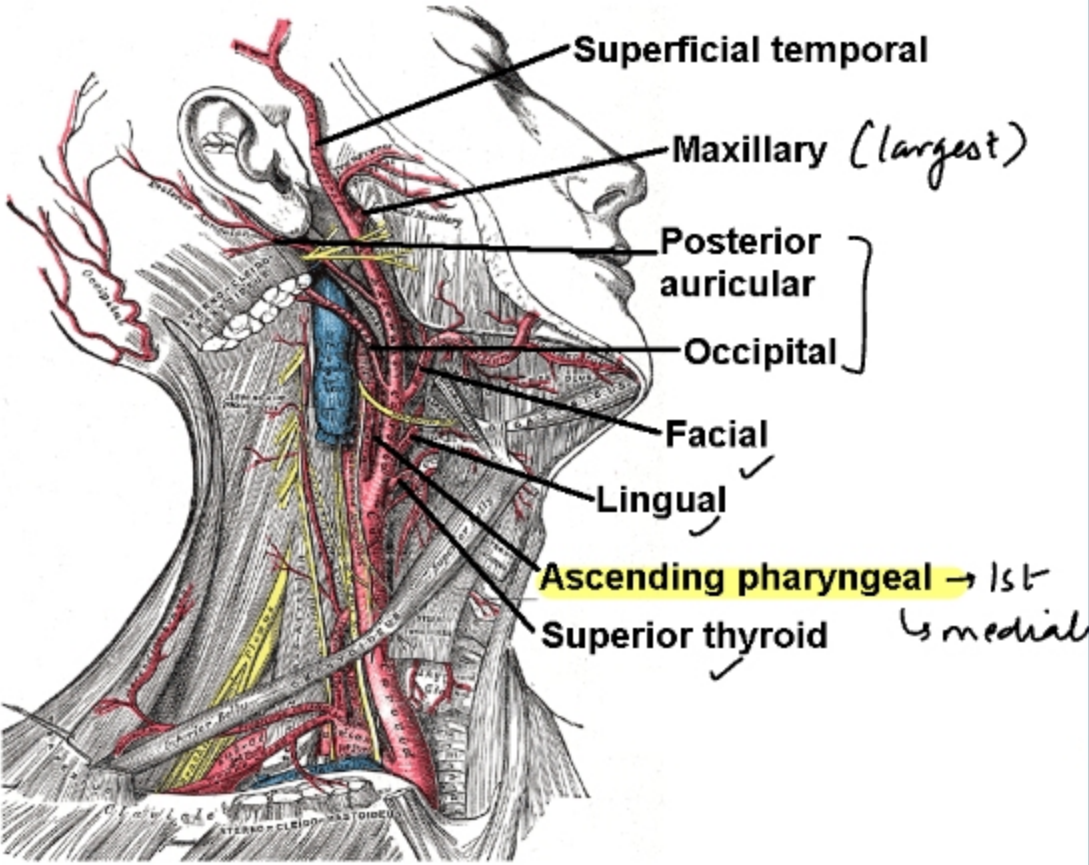
Structures piercing buccinator: Buccal N ( $V_3$ ) / Buccal A/V / Parotid duct

↑  
7th CN (except to Hilton law)  
supplies

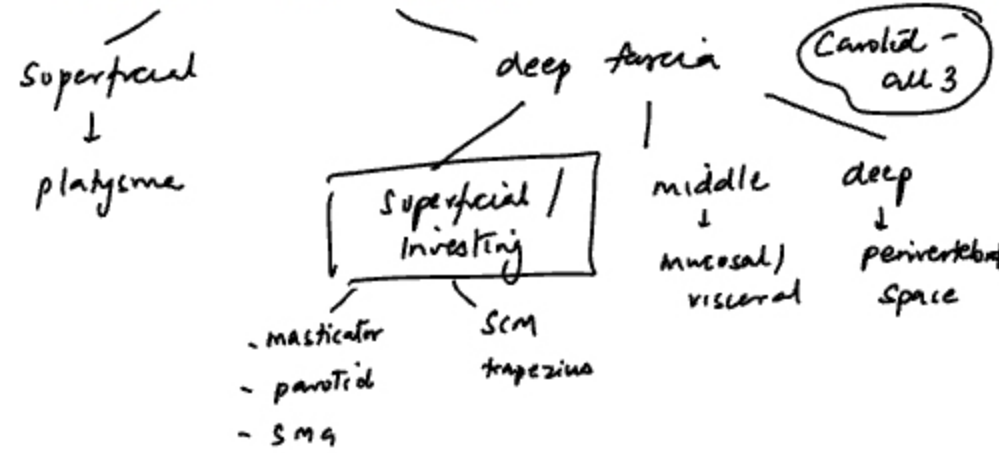
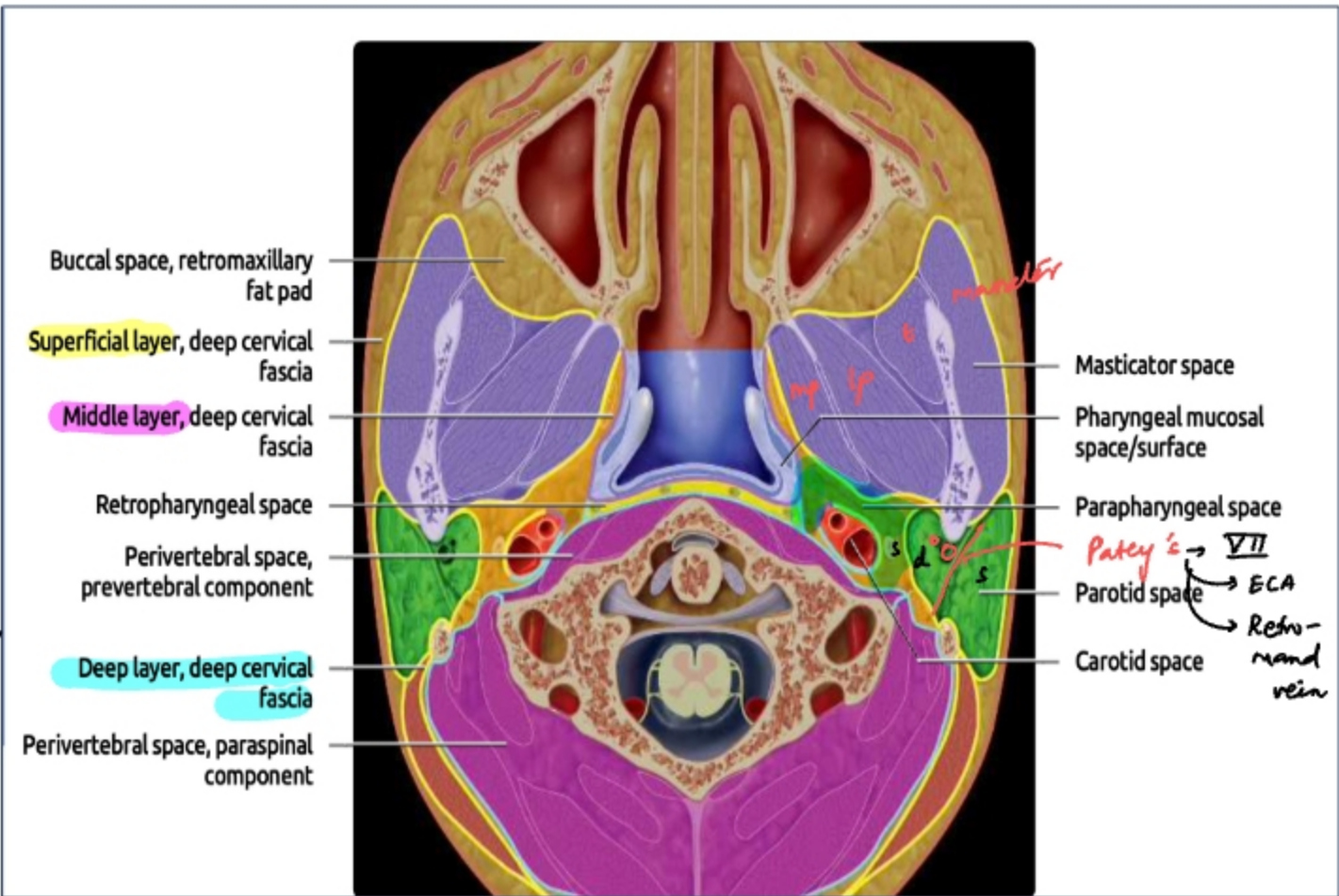


Danger area of face  
 facial vein → deep facial vein  
 ↓  
 pterygoid venous plexus  
 emissary vein → CS

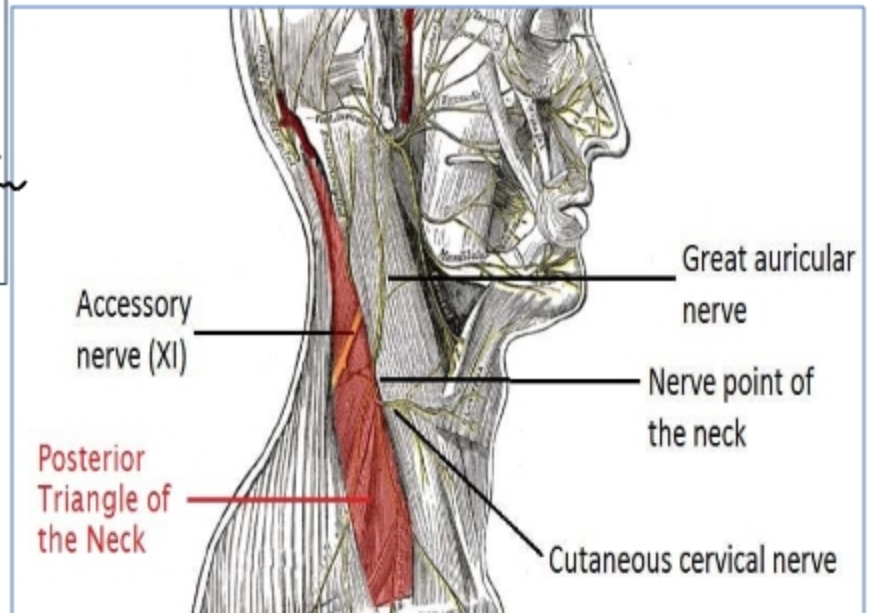
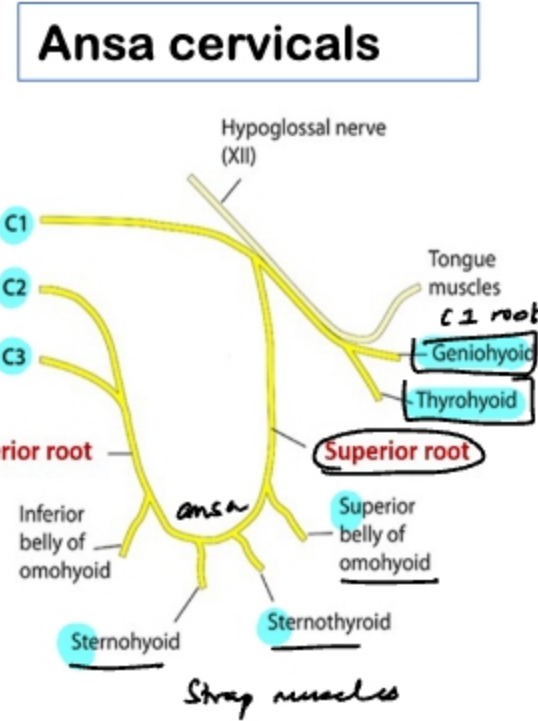
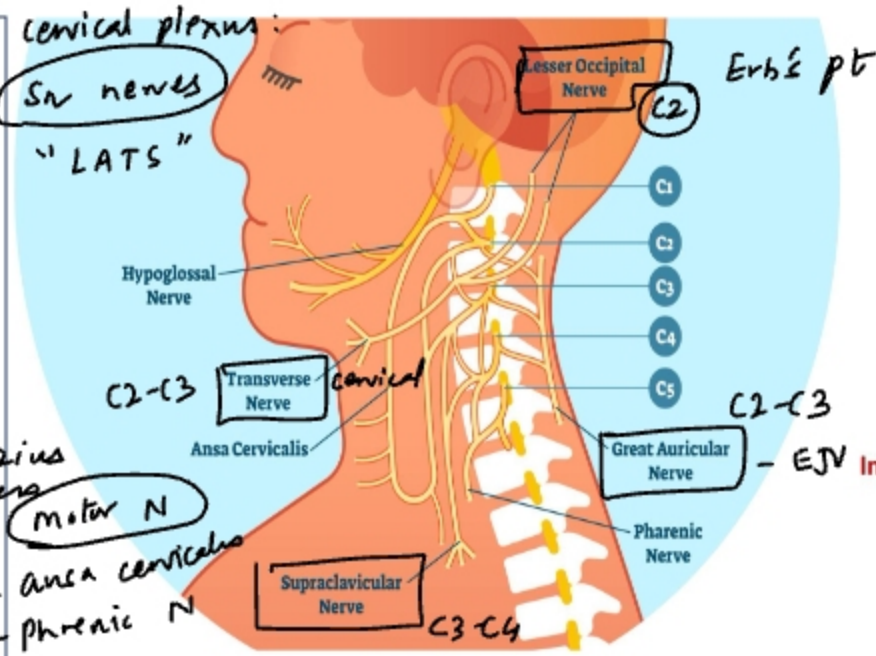
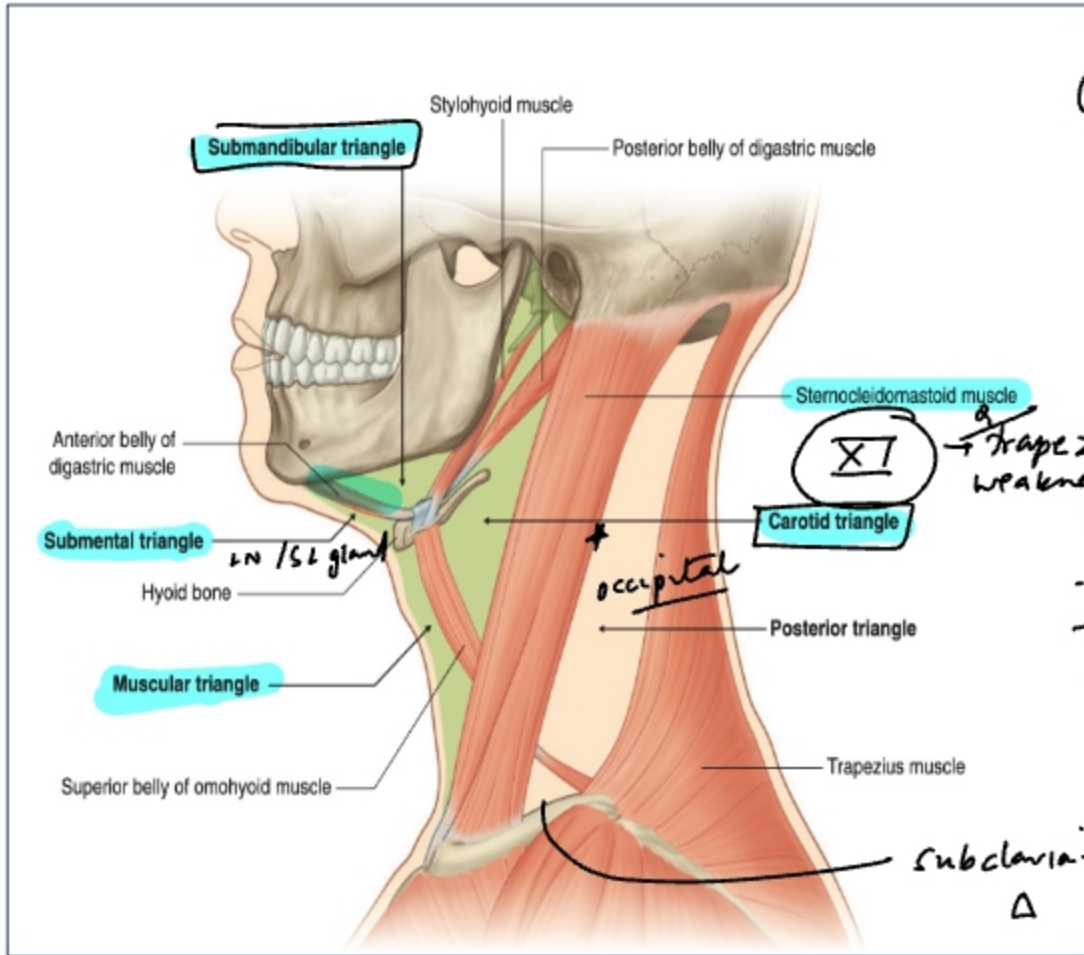




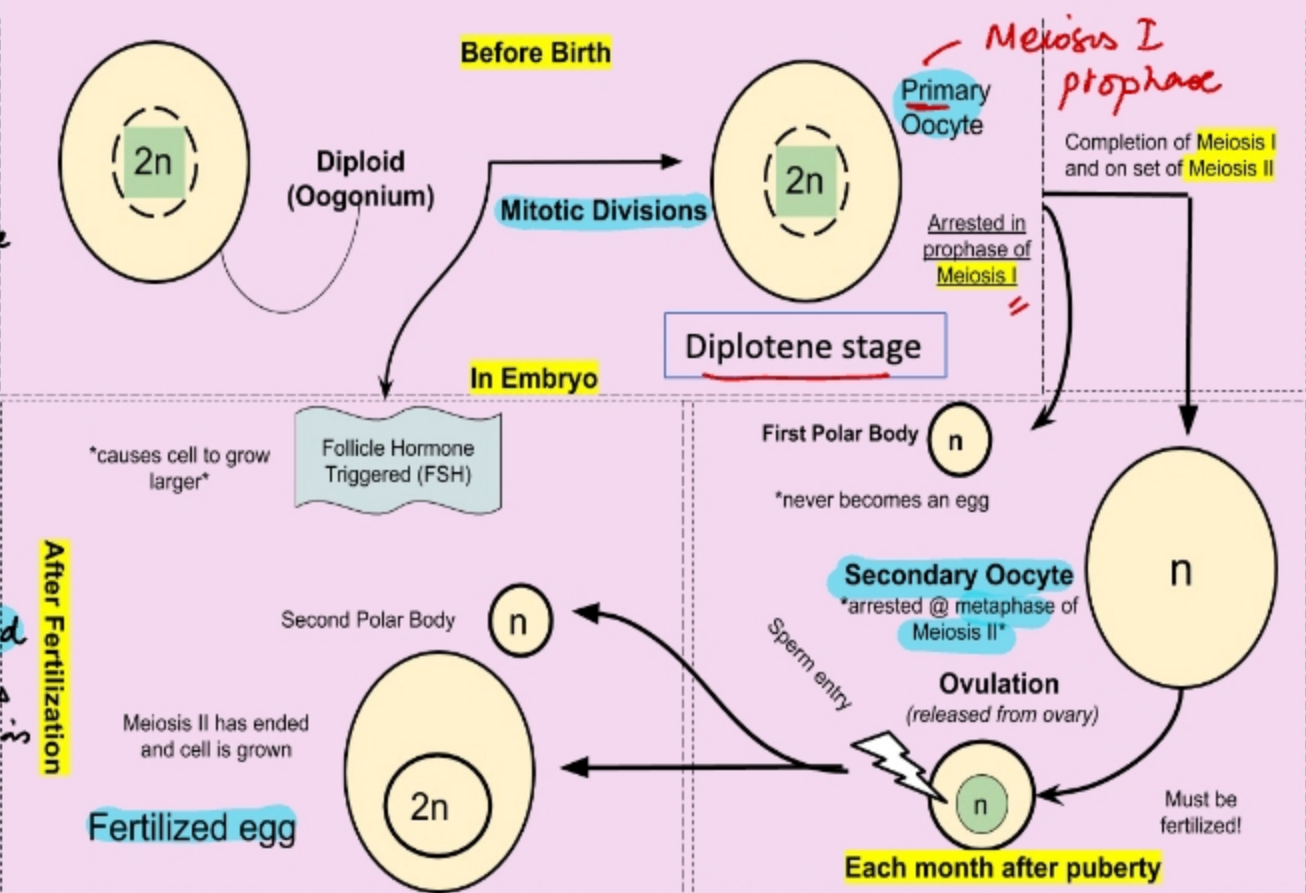
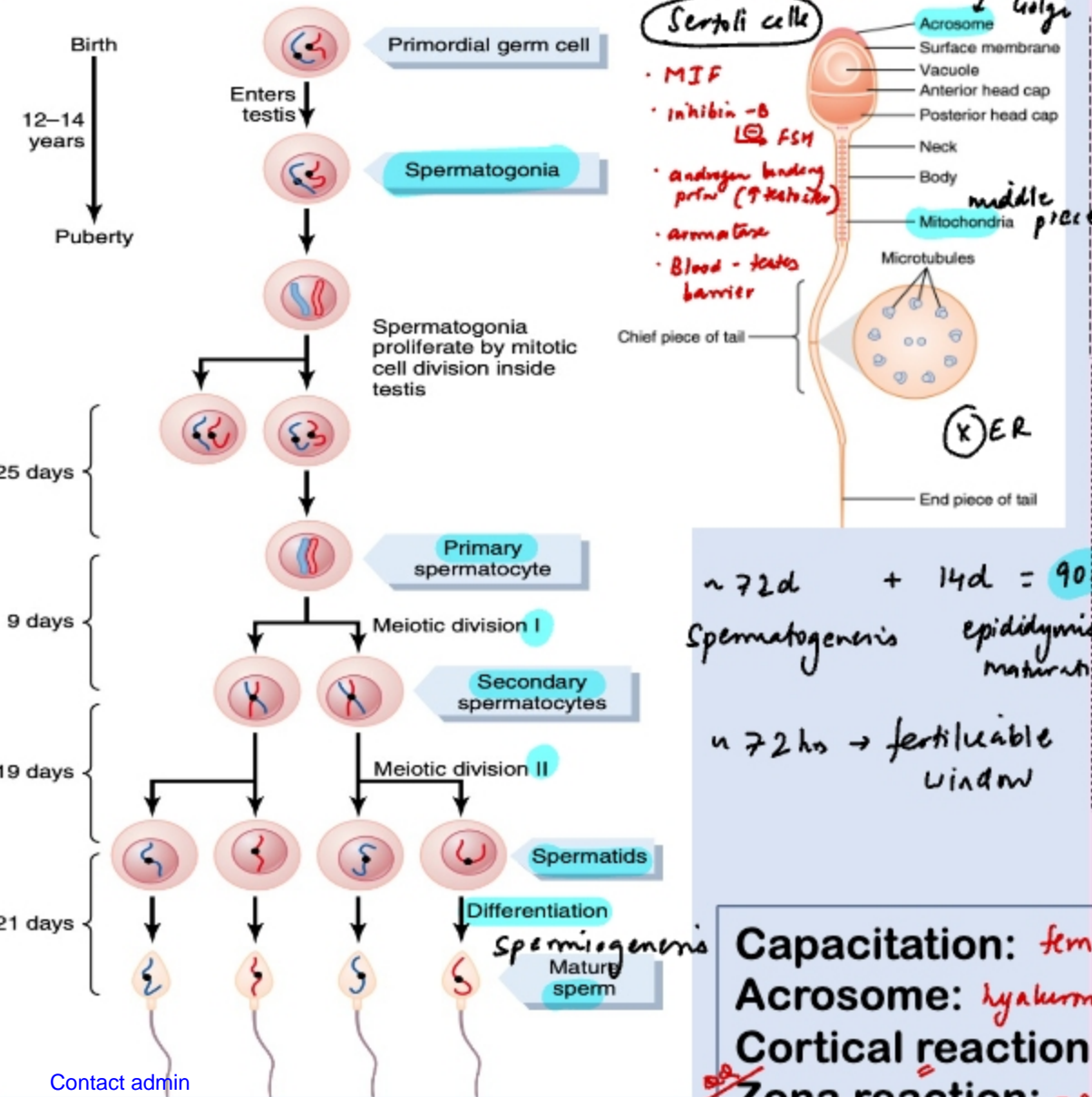
ECA



# Head and neck triangles



# Spermatogenesis-Oogenesis



**Spermatogenesis:**  $\sim 72d + 14d = 90d$  epididymis maturation

$\sim 72hs \rightarrow$  fertile window

**Capacitation:** female repr tract (FT)  $\rightarrow$   $\uparrow$  motility

**Acrosome:** hyaluronidase digest corona radiata

**Cortical reaction:** cortical granules released

**Zona reaction:** ZP hardening (ZP2/3) - polycpermy  $\downarrow$

$Ca^{2+}$  influx  $H103T$  influx

corona radiata ZP

ovum  $\rightarrow$  24hs fertile

d0 Fertilisation

d1-4 Cleavage - cell ÷

d3-4 Compaction

d5 Differentiation - trophoblasts

Cavitation (Cyt) - blastocyst

Hatching (ZP)

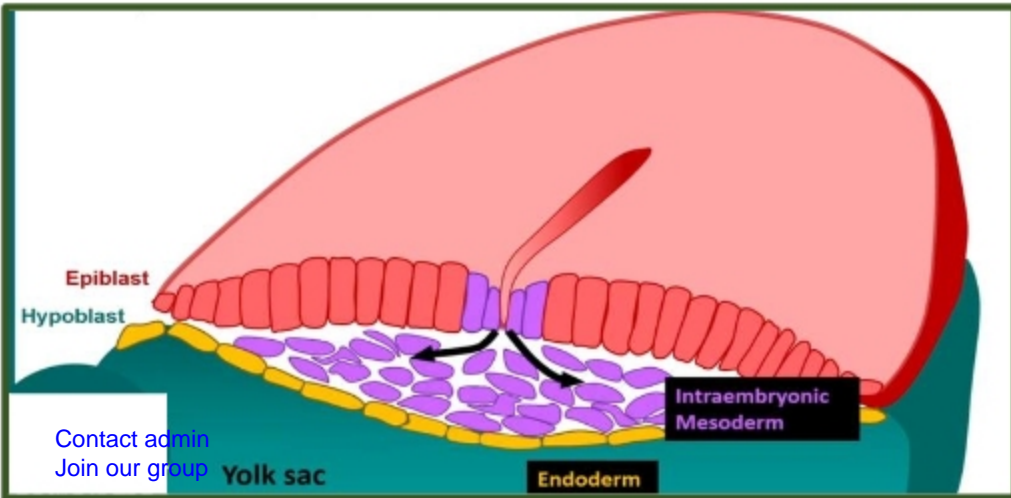
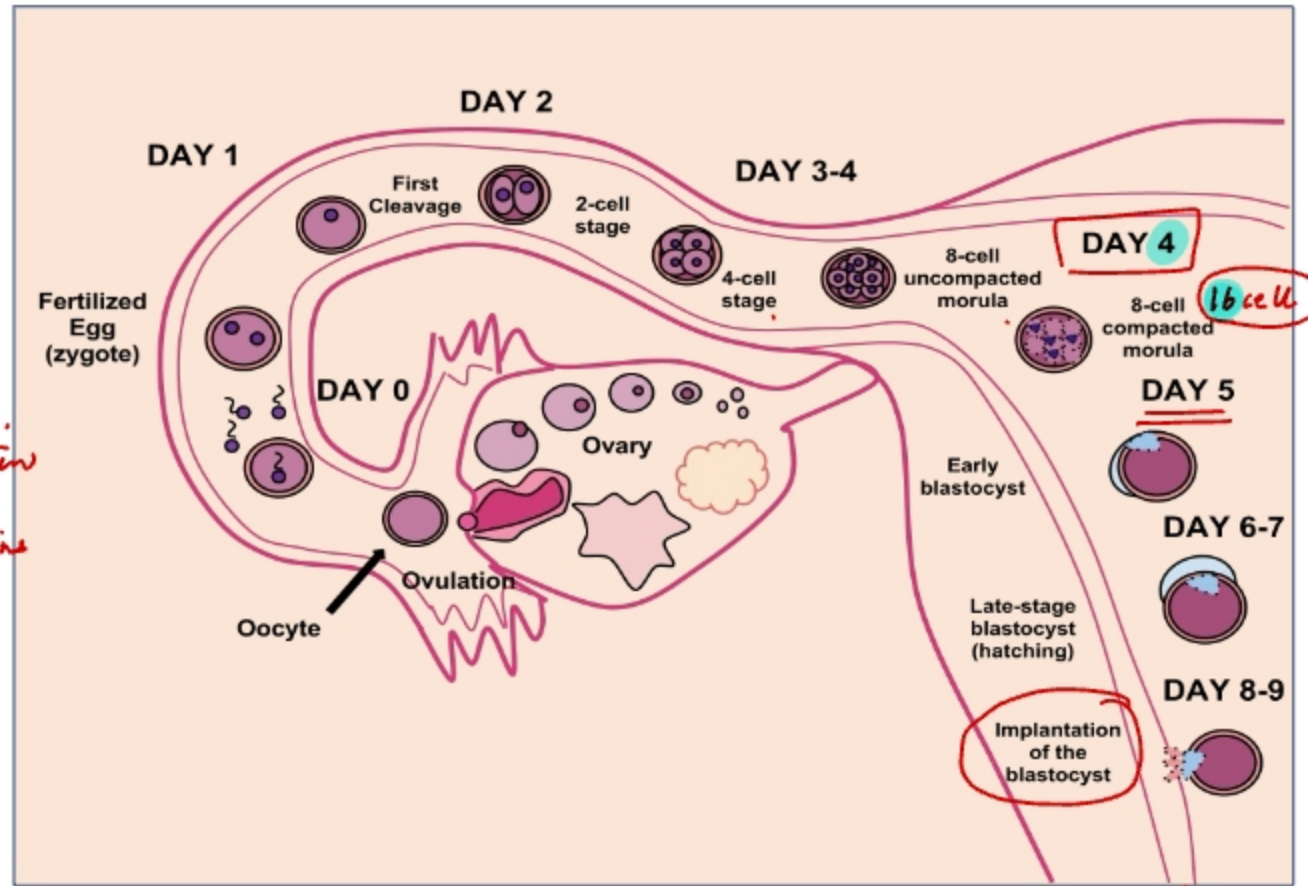
Implantation → d6 - d10

Bilaminar (2nd wk)  
AS epiblast  
YS hypoblast

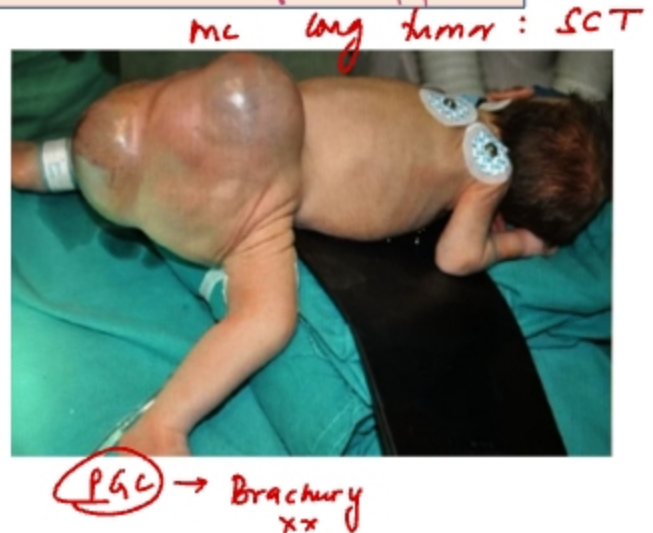
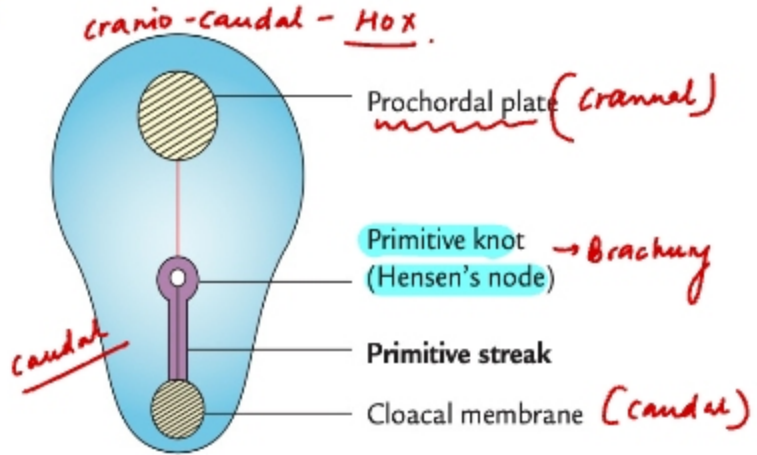
Gastrulation (3rd wk)

All layers from: Epiblast

apposition: L-selectin  
adhesion: Integrins  
invasion: MMPs  
1st → endo  
meso  
ectoderm



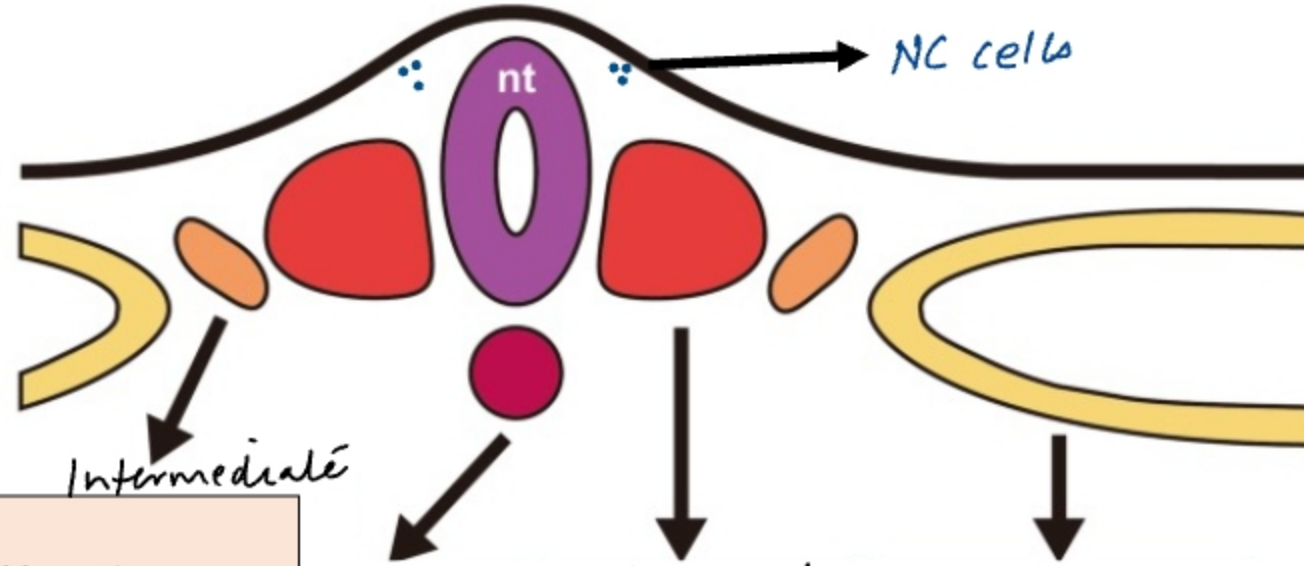
Contact admin  
Join our group



# Germ layer derivatives

## NEURAL CREST MOTEL PASSES

- M - Melanocyte
- O - Odontoblast - Dentin
- T - Tracheal cartilage
- E - ECF cells = APVD cells
- L - Leptomeninges
- p\* - Peripheral nervous system / ENS
  - ↳ Parafollicular C-cells
  - ↳ HD
- A - Adrenal medulla
- S - Schwann cells
- S - Spiral septum
  - Ao
  - PA
- E - Endocardial cushion
  - Atio-ventr septum
  - member VCD
  - AV / Semikunar valves
- S - Skull cartilage / Dermis of HBN



*Intermedial*

**GU system**  
Adrenal cortex  
Gonads

*Notochord*

**Nucleus pulposus**  
Tectorial membrane  
Apical ligament dens

*Paraxial*

**Dura**  
**SOMITES:**  
Axial skeleton  
Dermis of back  
Skeletal muscles  
Tongue / EOM

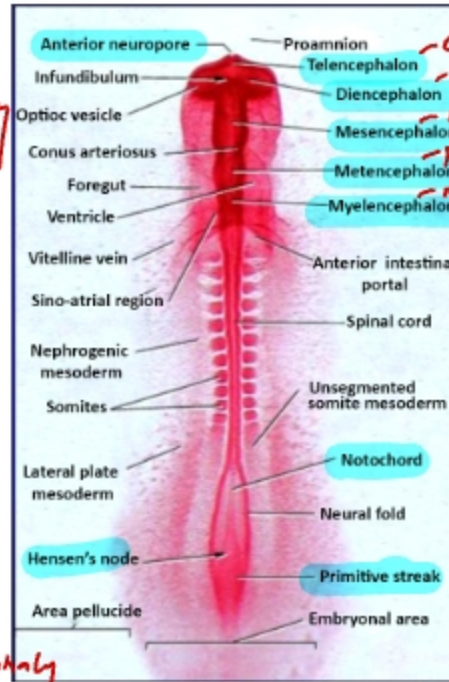
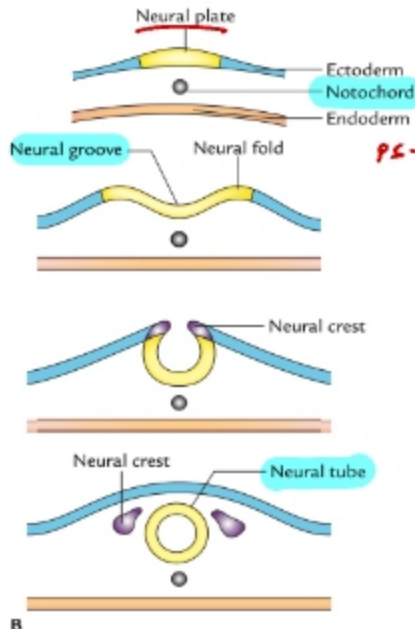
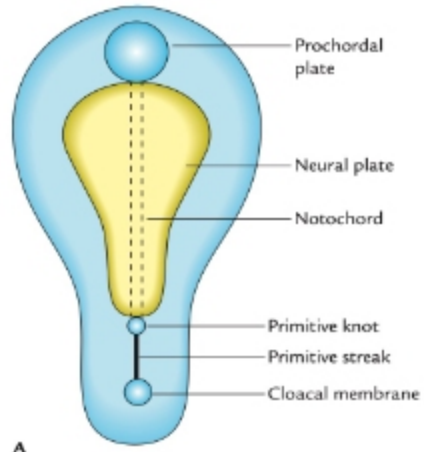
*Lateral plate*

**SOMATOPLEURIC:**  
Dermis of anterior torso, limbs  
Appendicular skeleton

**SPLANCHNOPEURIC:**  
Cardiac muscles  
Smooth Muscles  
**RES-Spleen, Microglia**  
Serosa, endothelium

**Adrenal cortex-** *mesod (Int)*  
**Adrenal medulla-** *NC*

**Dura-** *Paraxial mesod*  
**Leptomeninges-** *NC*



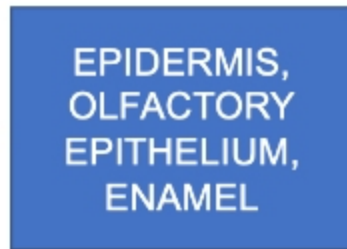
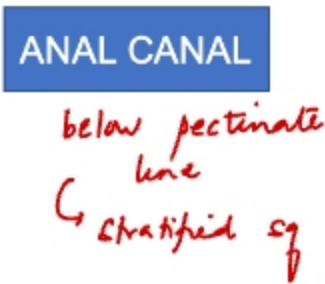
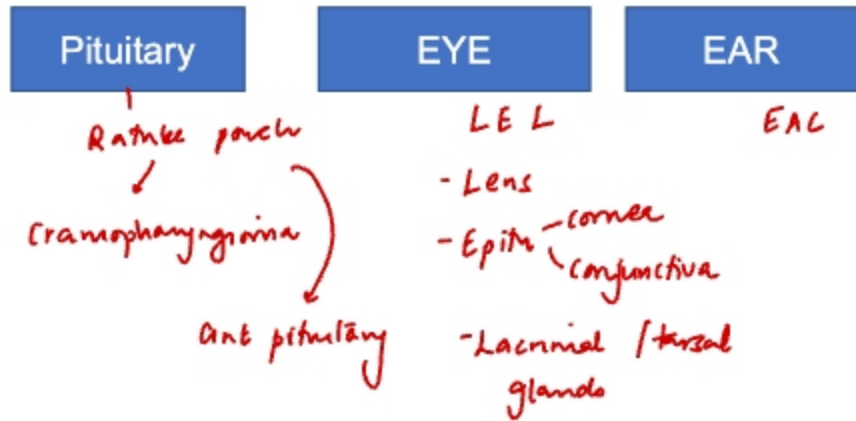
ant → d25 → anencephaly  
 post → d28 → spina-bifida

Intra-embryonic coelom - body cavities  
 pleural - pericardial  
 peritoneal

# Surface ectoderm

TM / vitreous - all 3 germ layers

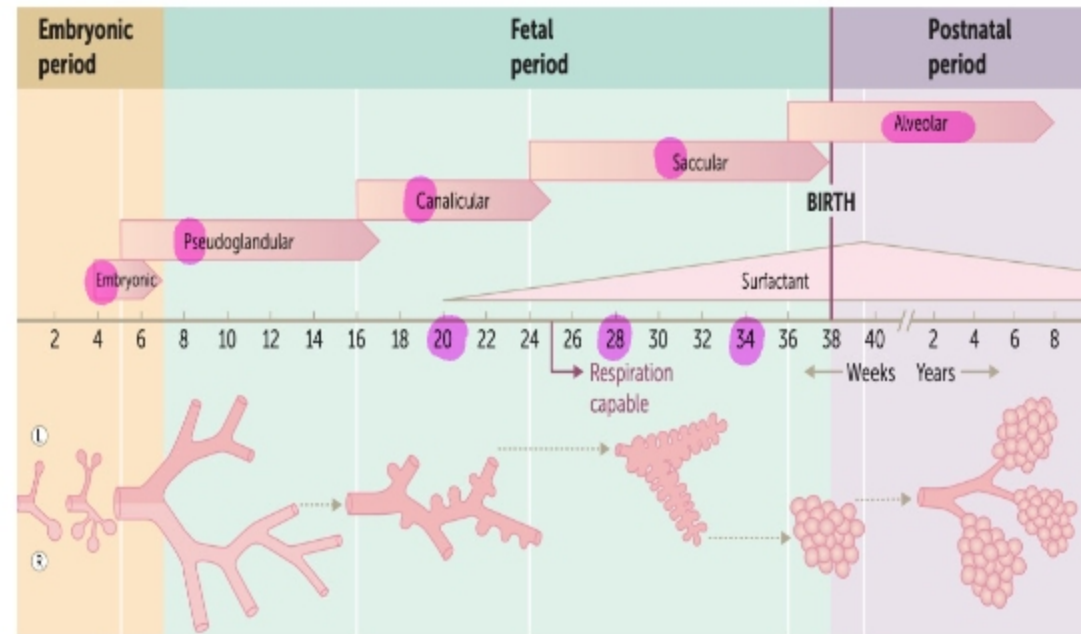
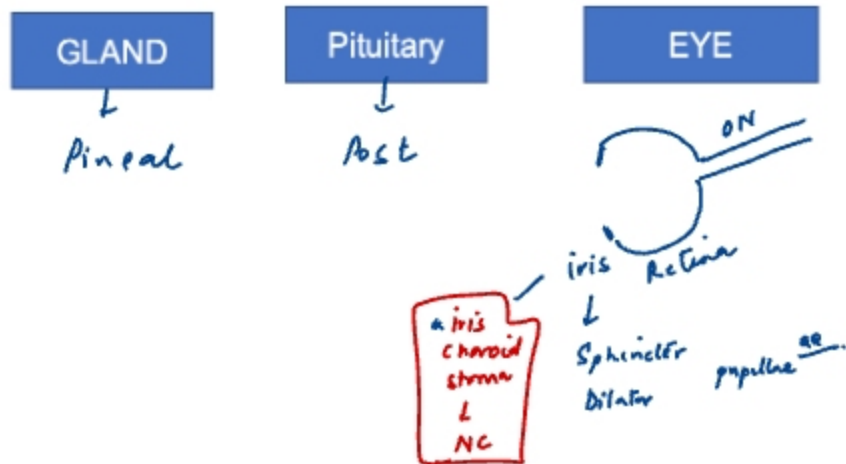
Enamel/ Ameloblast- ectoderm  
Dentin/Odontoblast- NC



# Neuroectoderm

**Endoderm:**  
Abdomen except spleen  
Urogenital sinus <sup>ae</sup>

- Brain - Neurons / Glial cells except glia
- spinal cord



# Urogenital system

**MESONEPHRIC DUCT** = Wolfian duct

**Caudal end-Ureteric bud:** CD - calyx - pelvis - ureter

**Males:** SEED - SV / epididymus / ejac duct / vas deferens  
trigone<sup>ae</sup>

**Females:**

Para-oophoron  
Ep-oophoron  
Gartner duct } broad lig  
VS Gartner duct cyst - anterior vag wall  
- cough + cystocele - reducible  
- rugae (+)

**PARAMESONEPHRIC DUCT** = Mullerian duct

**Males:**

P A T  
Prostatic  
utricle } appendix testis = Hydatid of Morgagni

**Females:**

FT, uterus, cx, upper 2/3 vagina  
lower 1/3 vagina - UGS

## Urinary system

**Kidney (Till DCT)** → Metanephric blastema

**Collecting system-**

**Trigone, post wall of urethra-**

**UB-**

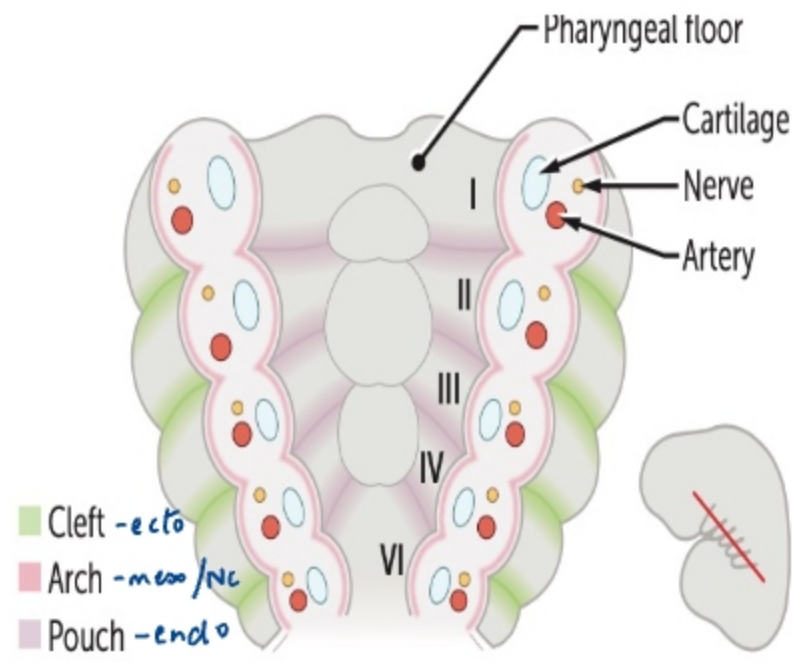
**Urethra-**

**Prostate-**

} Mesonephric duct  
} Urogenital sinus

Structure	Male derivative	Female derivative
Genital tubercle	Glans Penis	Clitoris
Genital fold	Ventral shaft of penis	Labia minora
Genital swelling	Scrotum	Labia majora
Genital ridge	Testes	Ovary

# Pharyngeal cleft-pouch derivatives



Cleft	Adult derivatives
1 <sup>st</sup>	External auditory meatus, tympanic membrane
2 <sup>nd</sup> - 4 <sup>th</sup>	Cervical sinus- obliterates; Persist as Brachial cyst/sinus

*mc: 2nd brachial cleft  
ant SCM - upper-mid 1/3*

Pouch	Adult derivatives
1 <sup>st</sup>	Middle ear cavity, Eustachian tube, Mastoid, Tympanic membrane
2 <sup>nd</sup>	Epithelial lining of crypts of palatine tonsil; including crypta magna
3 <sup>rd</sup>	Thymus, Inferior parathyroid glands
4 <sup>th</sup>	Superior parathyroid glands Ultimobranchial body (5 <sup>th</sup> remnant)

*THird*

*"tonsil"*

*Parafollicular C-cells - NC*

*Digeorge Sx - 22q del  
↓Ca<sup>2+</sup> + Tcell dysfn*

All tongue muscles supplied by XII  
 All palatal muscles supplied by ELN  
 All pharyngeal muscles supplied by ELN  
 All laryngeal muscles supplied by RLN

except Palatoglossus → ELN  
 except tensor veli palatini → V3  
 except cricopharyngeus → RLN  
 except cricoid → ELN

Contact admin  
 Airway group

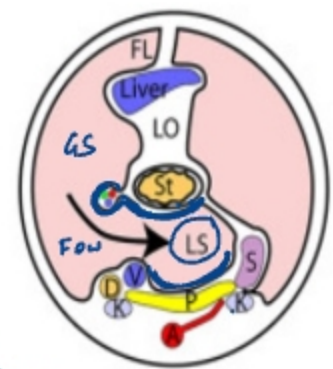
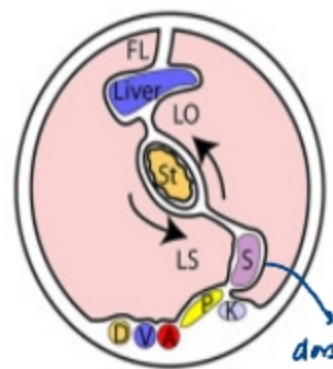
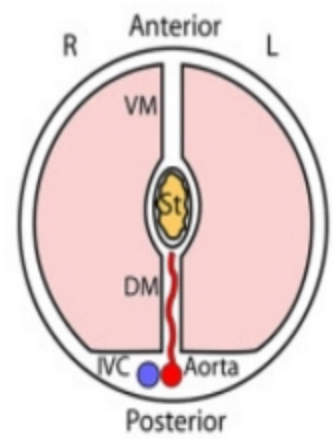
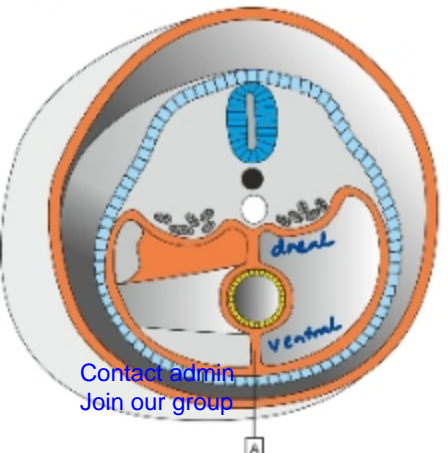
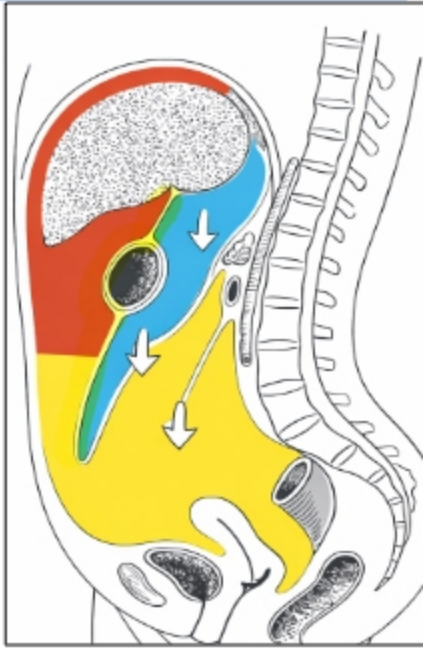
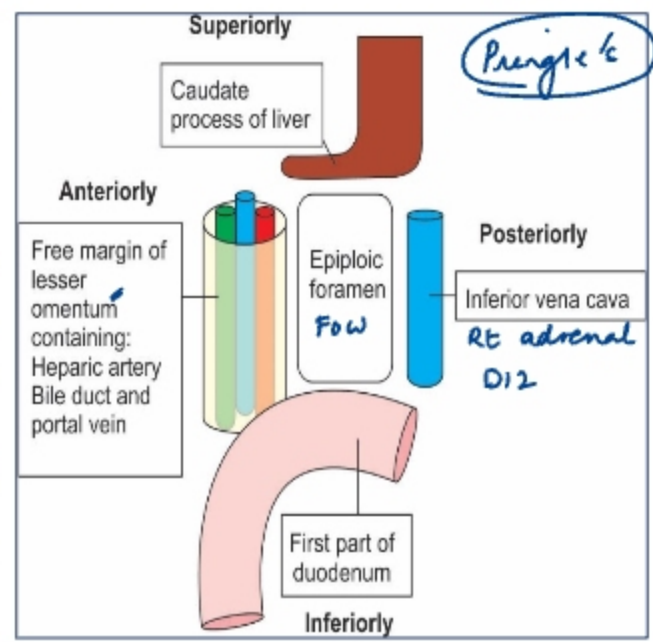
# Pharyngeal arch derivatives

Pharyngeal arch	Bones	Muscles	Nerve	Artery
1 <sup>st</sup> <i>M</i>	Meckel's cartilage, Maxilla, Mandible, Malleus and incus, zygomatic bone, sphenomandibular ligament	Muscles of mastication, Mylohyoid, Anterior belly of digastric, Tensor veli palatini,	V3	Maxillary artery
2 <sup>nd</sup> <i>S</i>	Reichert's cartilage, Stapes (Except Footplate-Otic capsule), Styloid process, Lesser horn/ Sup body of hyoid bone, Stylohyoid ligament	Muscles of facial expression, Stylohyoid, Stapedius, Buccinator, Platysma, Posterior belly of digastric	VII	Stapedial artery
3 <sup>rd</sup>	Hyoid bone (Inferior Body and greater horn)	<u>Stylopharyngeus</u>	<u>IX</u>	Common carotid and internal carotid <i>CCA / ICA</i>
4 <sup>th</sup> <i>//</i>	Laryngeal cartilages (except epiglottis-hypobranchial eminence)	Cricothyroid, Levator palatini, Pharyngeal constrictors <i>palatal muscles</i> <i>"ph plexus"</i>	Vagus nerve (X) Superior Laryngeal nerve <i>ELN motor</i> <i>ILN SN</i>	Left: Aortic arch Right: Proximal right subclavian artery <u>RSCA</u> (+ 7 <sup>th</sup> intersegmental artery + Dorsal Aorta)
6 <sup>th</sup> <i>//</i>		All intrinsic muscles of larynx (except cricothyroid) <u>Cricopharyngeus</u>	Vagus nerve (X) Recurrent laryngeal nerve	PA DA (L6) <i>RLN - L6 - hook arnd lig arteriosum</i>

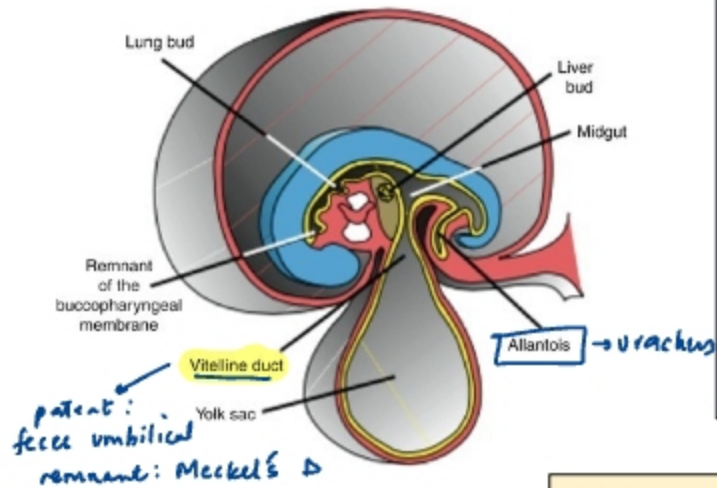
# Miscellaneous

Ventral mesentery derivatives	Dorsal mesentery derivatives
<b>Lesser omentum</b> Hepatogastric- R/L GA Hepatoduodenal - Portal Δ	<b>Greater omentum</b>
<b>Falciform ligament</b> - umb vein - lt lig teres hepatis	<b>Gastrosplenic ligament</b> - LE GE / Short gastric
<b>Triangular ligament of liver</b>	<b>Lienorenal ligament</b> - Splenic vessels tail of pancreas
<b>Coronary ligament of liver</b>	<b>Gastrophrenic ligament</b>
	<b>Mesentery of SI, mesoappendix</b>
	<b>Transverse/ sigmoid mesocolon</b>

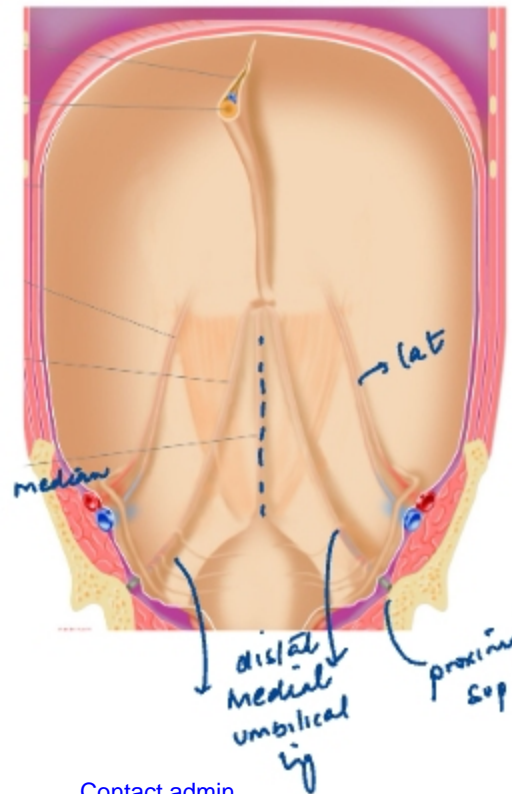
Prevents descent of spleen: *Phrenico-colic lig*



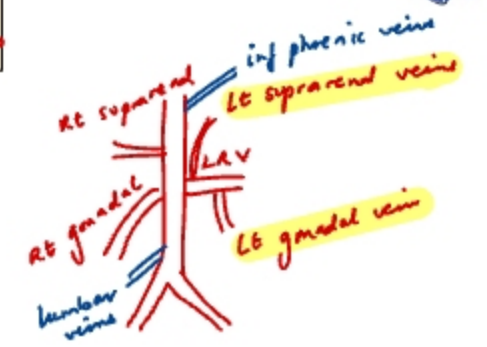
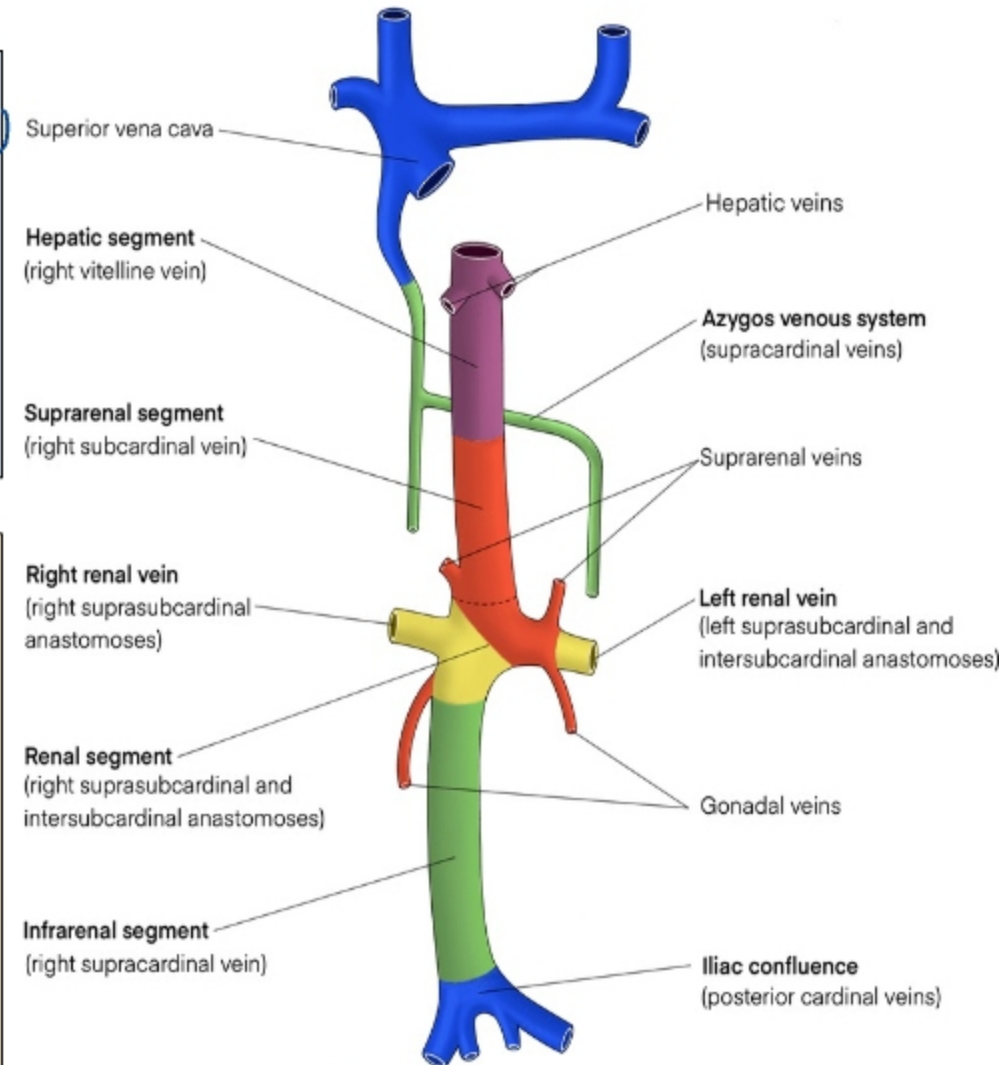
- Lesser sac: Anterior Boundary: **Lesser omentum, stomach, gastrocolic ligament (ant GO)** *HD lig*
- Posterior Boundary: **Post GO, Pancreas, upper left kidney, left adrenal gland, and the diaphragm**



**UMBILICAL LIGAMENTS**  
**MEDIAN-** *urachus (patent - urine - umbilicus)*  
**Umbilical artery**  
 Proximal: *sup vesical A*  
 Distal: *medial umbilical lig*  
**LATERAL-** *lig epig A*  
**Left Umbilical vein-** *lig teres hepatis*

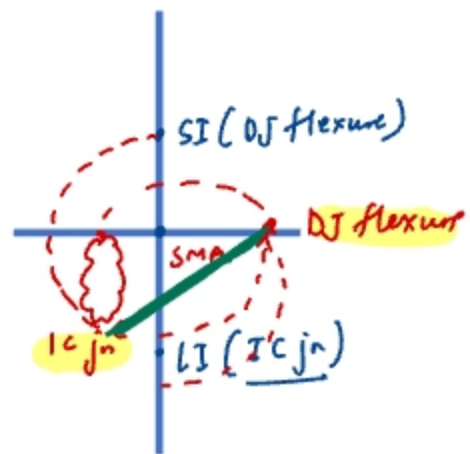


**Supracardinal Vein:** *Infra-renal IVC*  
*Azygos / Hemiazygos vein*  
**Subcardinal Vein:** *Suprarenal IVC*  
*LRV - Suprarenal veins / Gonadal veins (R/L)*  
**Sub-Supracardinal Anastomosis:** *Renal IVC*  
*Rt renal vein*  
**Posterior cardinal veins:** *common iliac veins*  
**Anterior cardinal veins:** *Brachioceph veins*  
**Rt CCV + Rt ACV:** *SVC*  
**Vitelline vein:** *PV, hepatic sinuoids, hep veins*

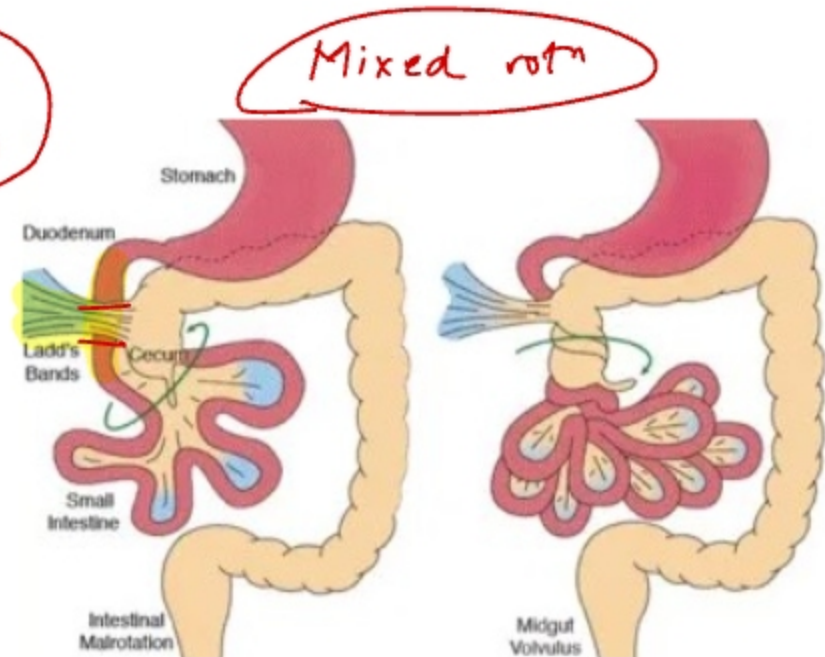
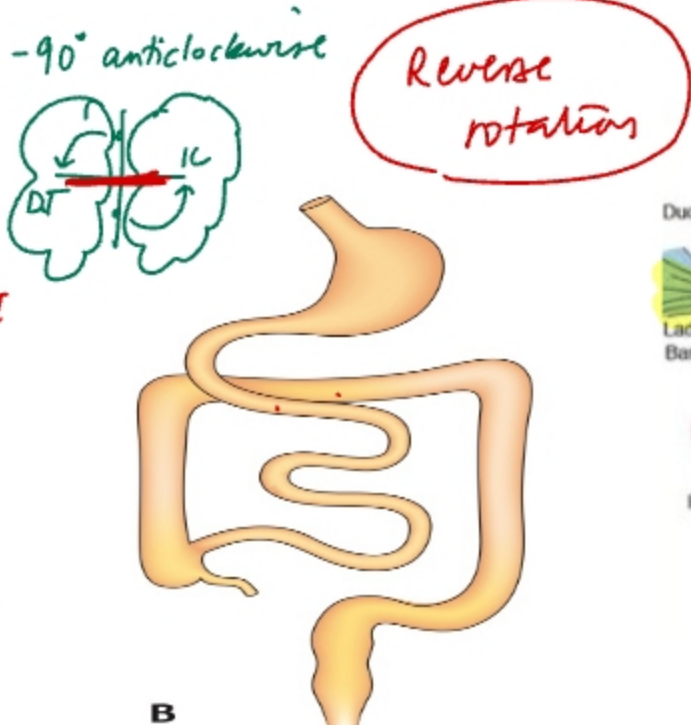
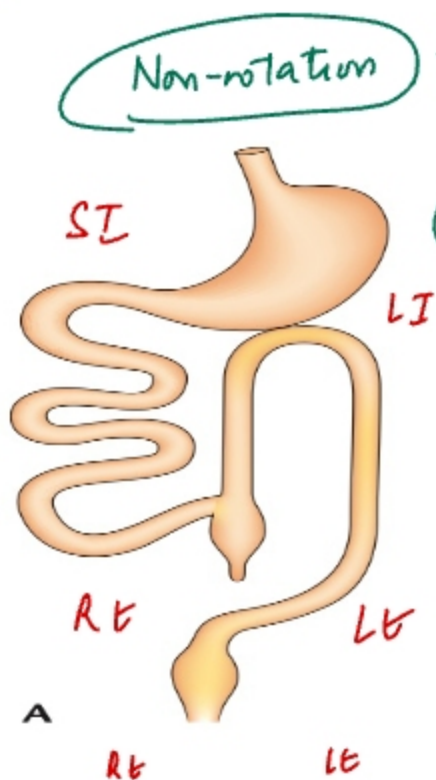


# Gut rotation - Malrotation

(N) : 270° anticlockwise



9-11wks : physiological

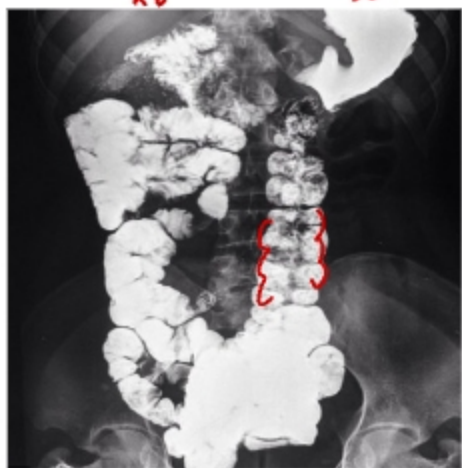

Sub-pyloric cecum

Ladd bands → Double bubble

**Incomplete rotation:**

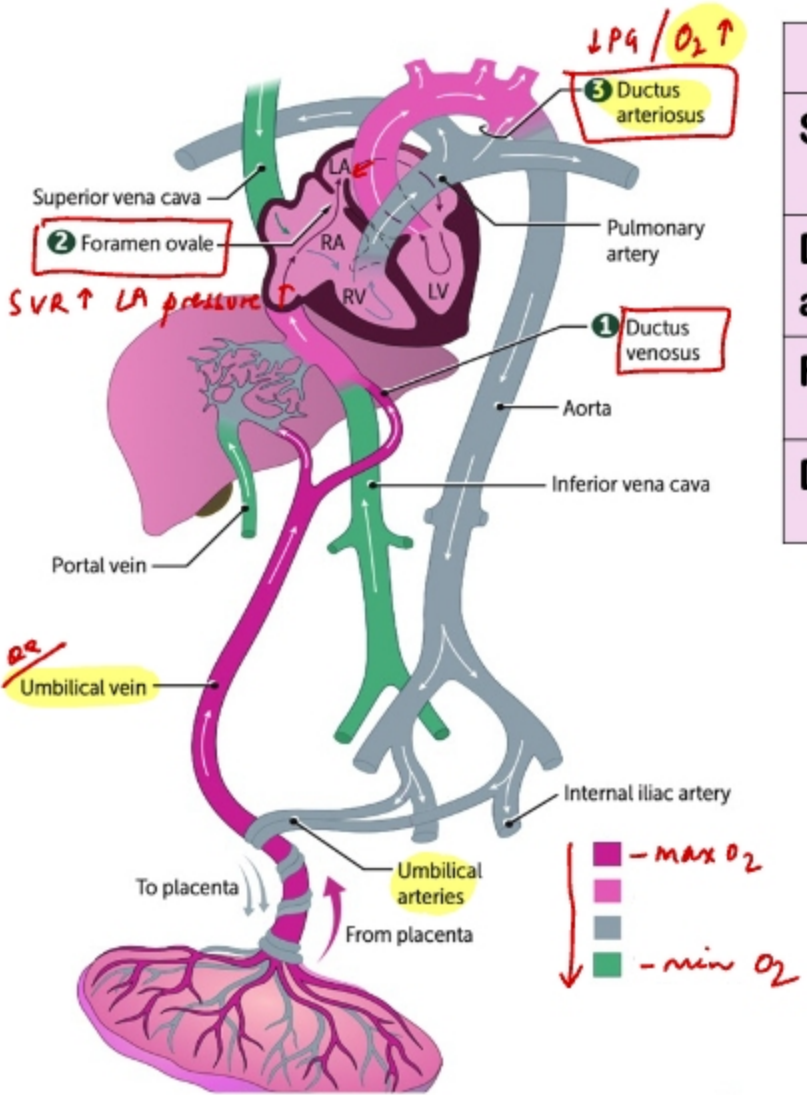
Subhepatic cecum



midgut  
volvulus  
|  
malrotn

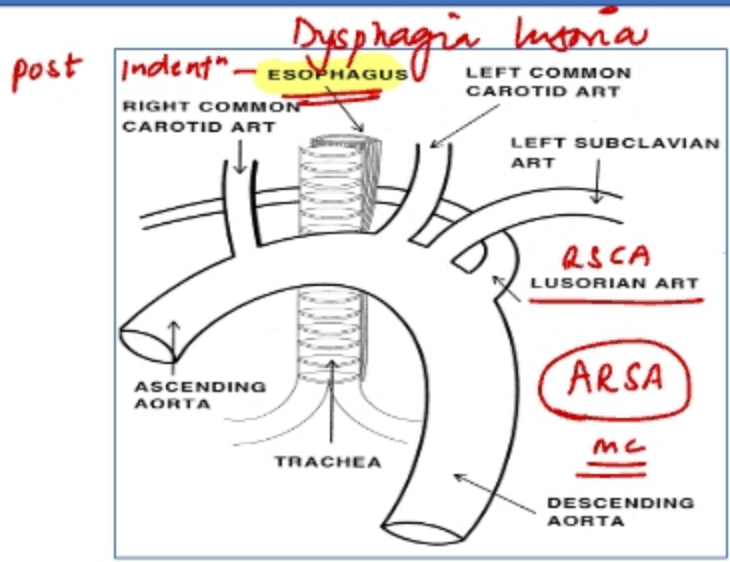
Duodenum  
ant to  
transv colon  
↓  
LBO  
==

# Fetal circulation

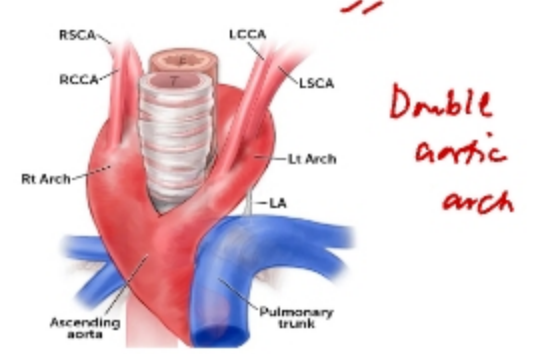


Changes After Birth: Closing of Shunts		
Shunt	Functional closure	Anatomical closure
Ductus arteriosus	2-3d (10-15hrs)	2 - 3 wks
Foramen ovale	Within mins	One year
Ductus venosus	Within mins	3 - 7 days

V or A  
 V A O  
 1wk 2wk 1yr

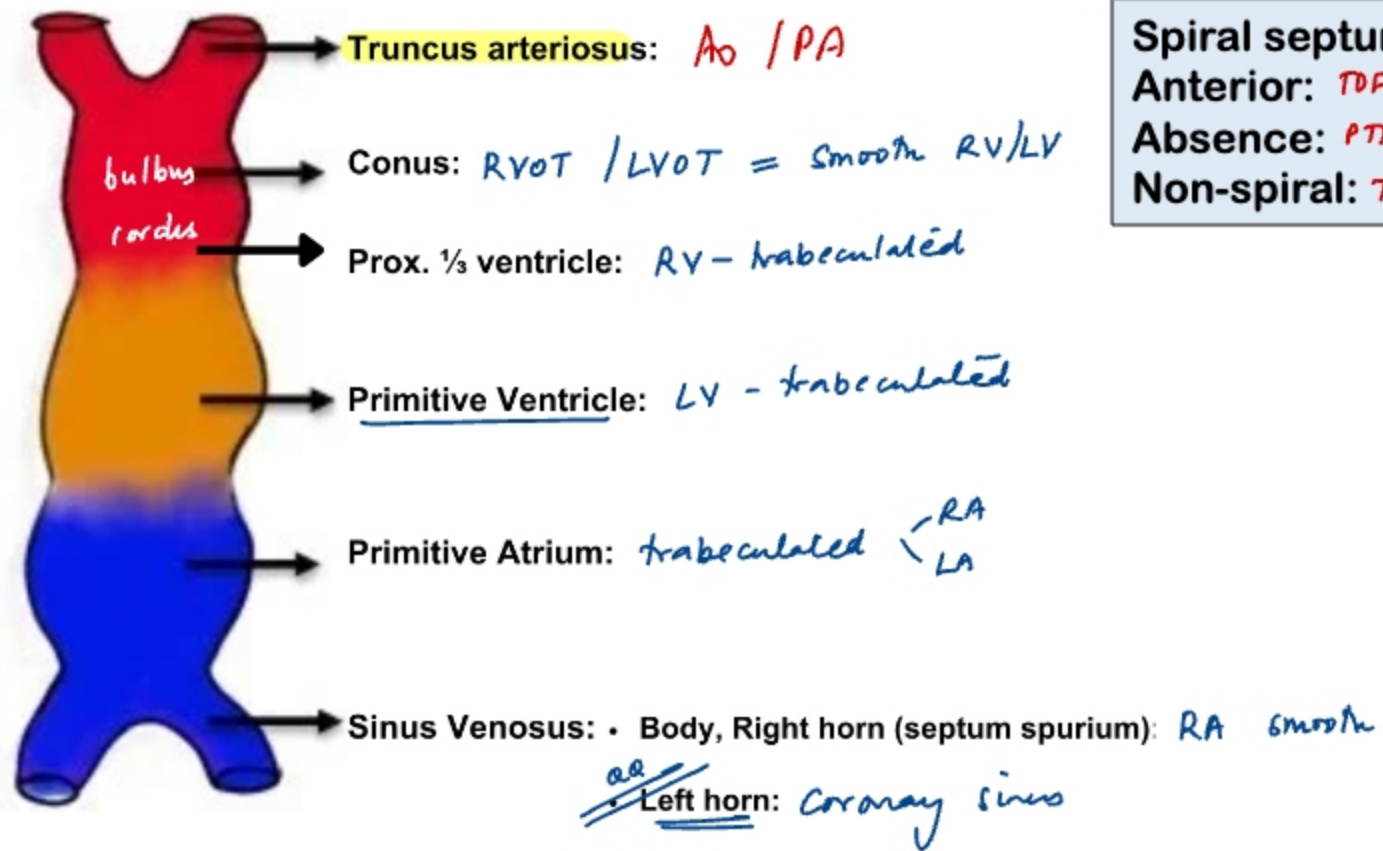


Obliteration of R 4th arch A + Persistence of caudal part of R dorsal aorta

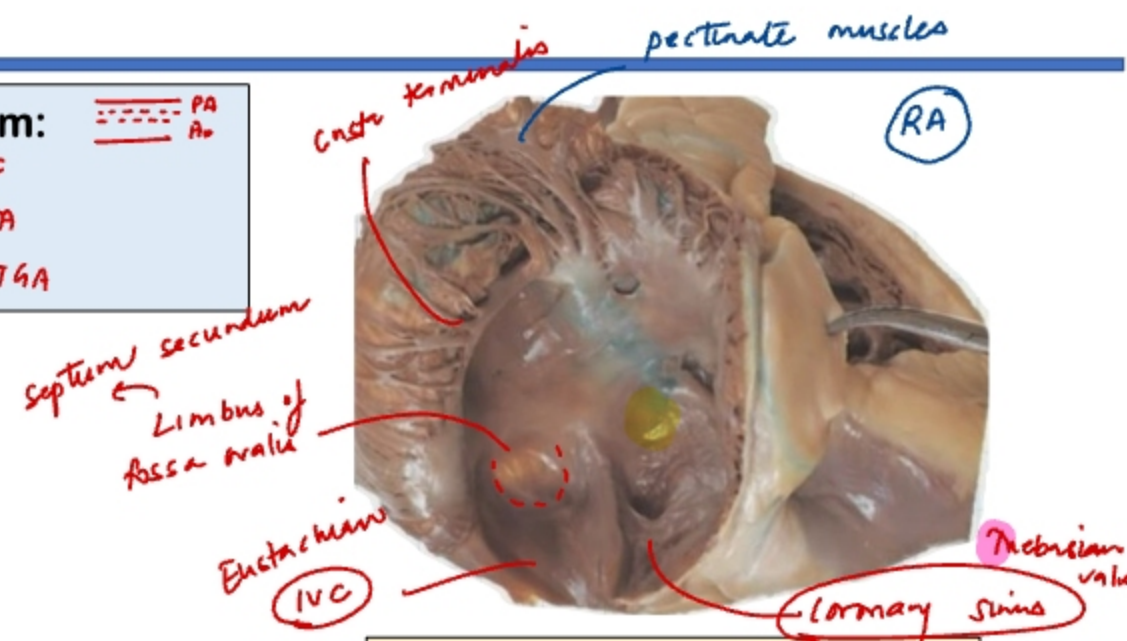


Persistence of R 4th arch A + caudal part of R dorsal aorta

# Heart-embryology

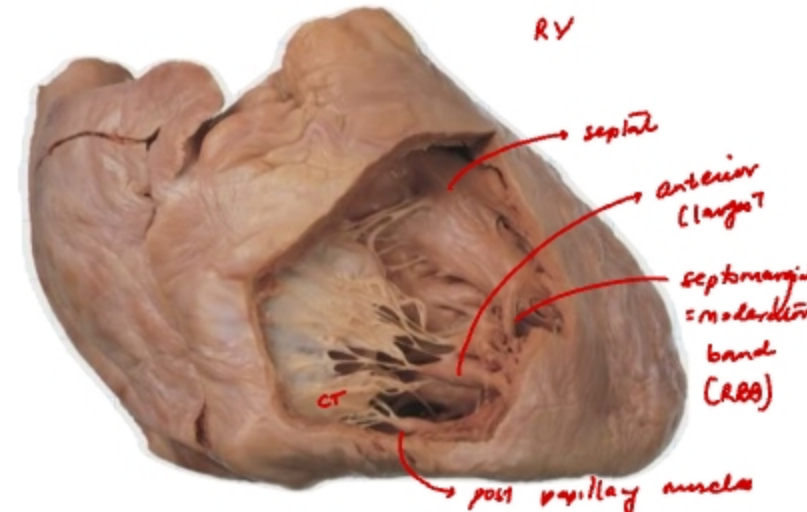
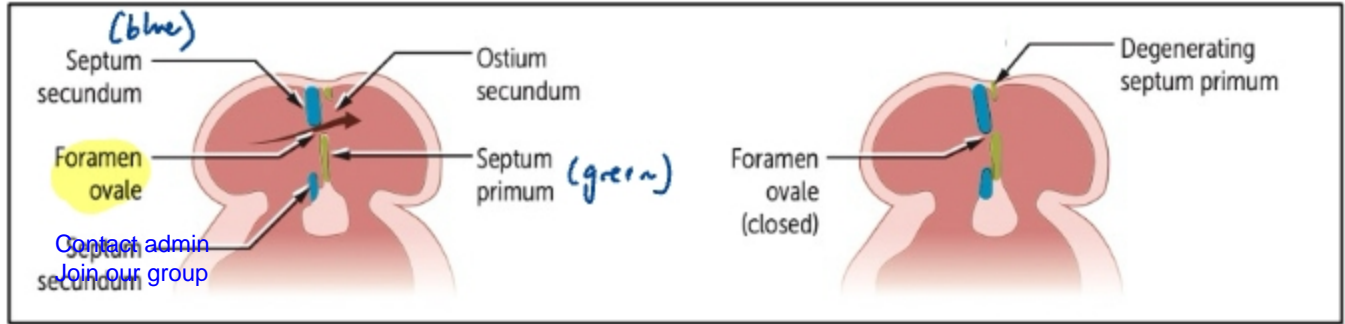


**Spiral septum:** PA, Ao  
**Anterior:** TDF  
**Absence:** PTA  
**Non-spiral:** TGA

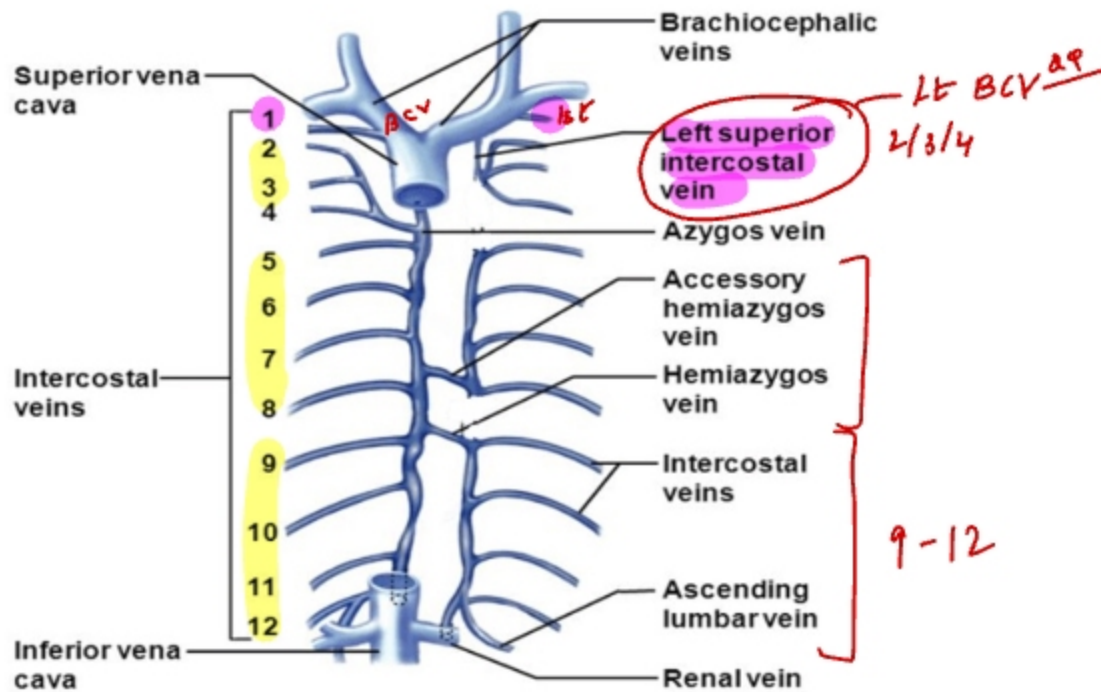


**Triangle of Koch** (AVN)  
 1. Tricuspid Septal leaflet  
 2. Tendon of Todaro → Bundle of His  
 3. Ostium of CS

**Primitive pulmonary vein:** smooth LA



# Azygos vein



*Azygos vein*

Formed by: **Right Lumbar azygos, right subcostal, right ascending lumbar**

Tributaries:

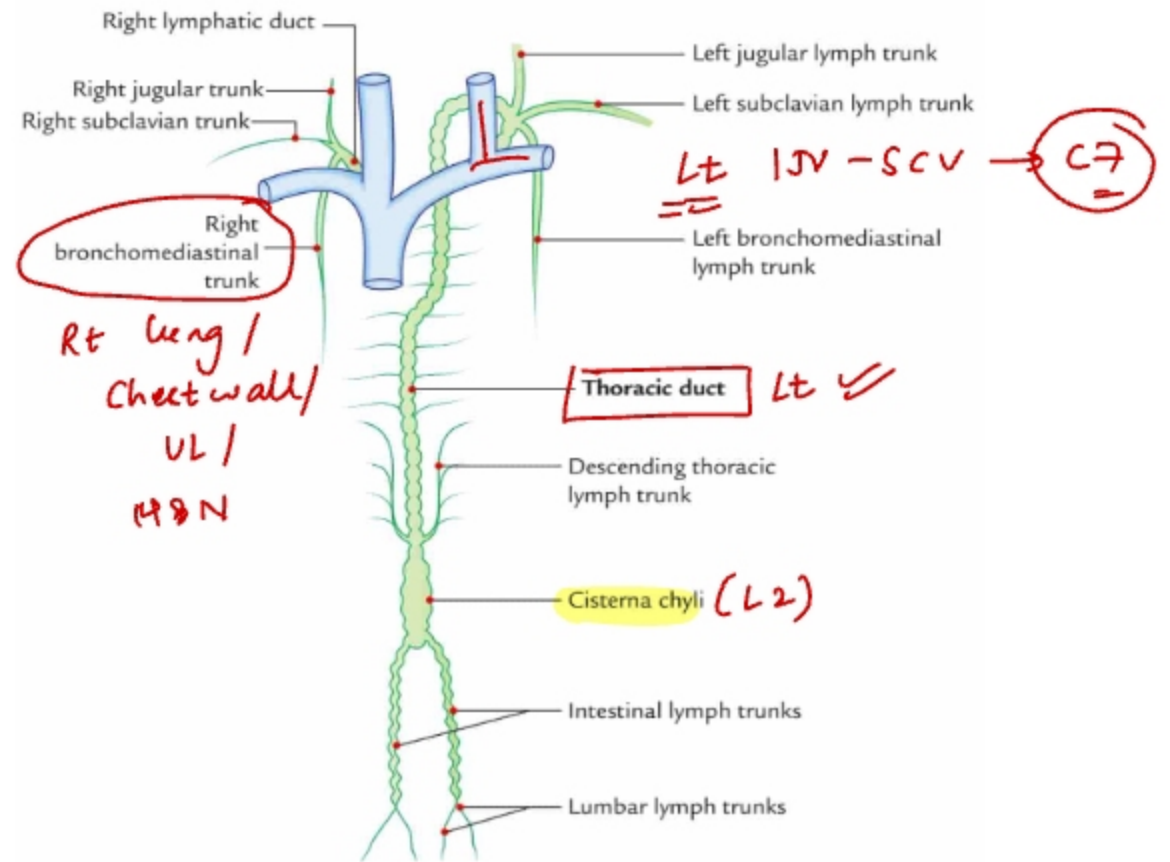
Right superior intercostal vein: 2,3,4 PICV

Right 5-11<sup>th</sup> PICV

Hemiazygos, Accessory hemiazygos-T8

T4 > SVC  
 Contact Admin  
 Join our group

# Thoracic duct



*Hemi-azygos*

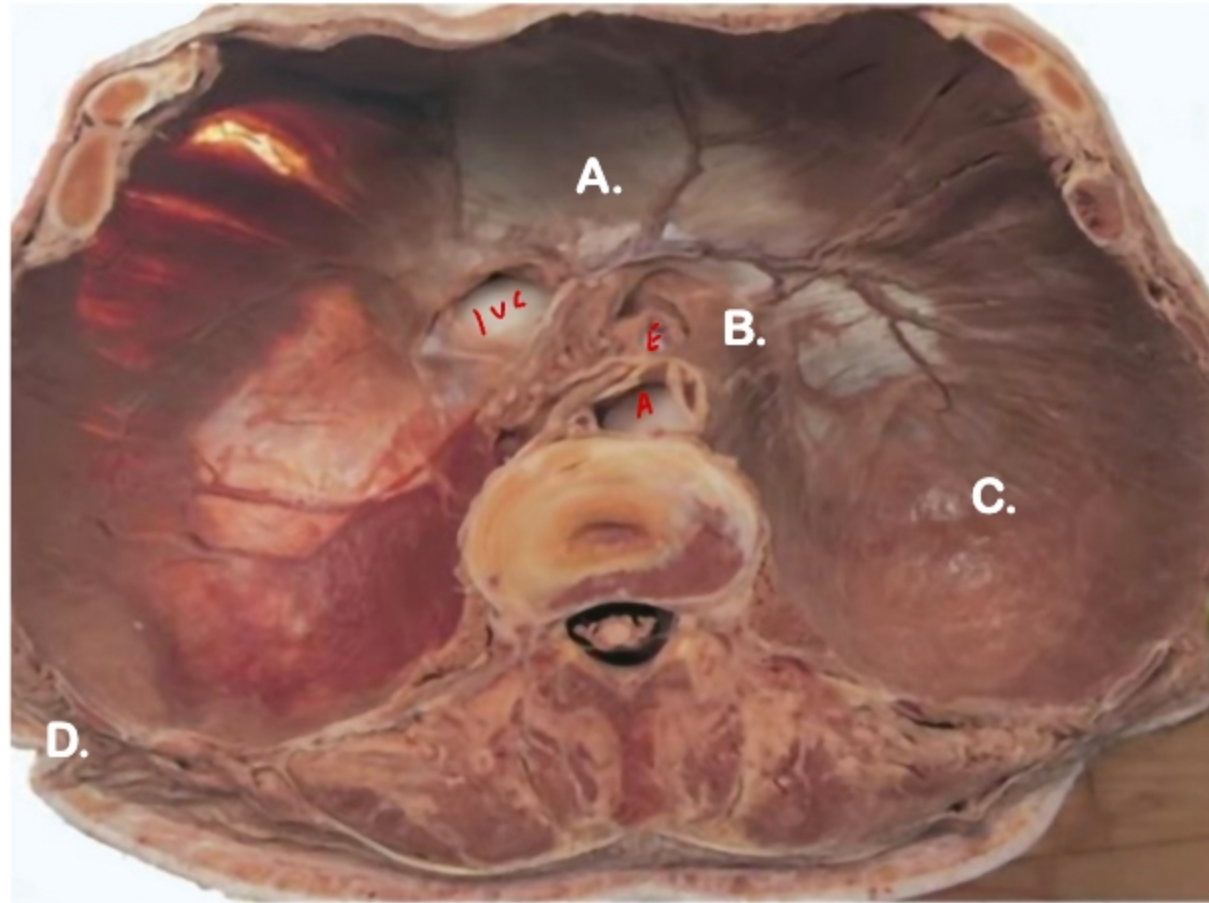
Formed by: **left Lumbar azygos, left subcostal, left ascending lumbar**

Tributaries: **Left 9-11<sup>th</sup> PICV**

*Accessory Hemi-azygos*

Tributaries: **Left 5-8<sup>th</sup> PICV**

# Diaphragm



I8  
 (T6) - IVC  
 Rt phrenic N

10 Eggs  
 (T10) - Esophagus  
 X  
 LGA

AAT 12  
 (T12) - Aorta  
 Azygos vein  
 Thoracic duct

- A. Central tendon - Septum transversarium  
 (LP mesoderm)  
 stroma liver  
 ventral mesentery
- B. Mesentery of esophagus
- C. Pleuro-peritoneal membrane → Bochdalek's
- D. chest wall somites - C3/4/5  
 Phrenic N

Space of Larrey = Foramen of Morgagni

Superior epigastric vessels

Behind lateral arcuate ligament

Subcostal vessels and nerve

Behind medial arcuate ligament

Sympathetic nerve

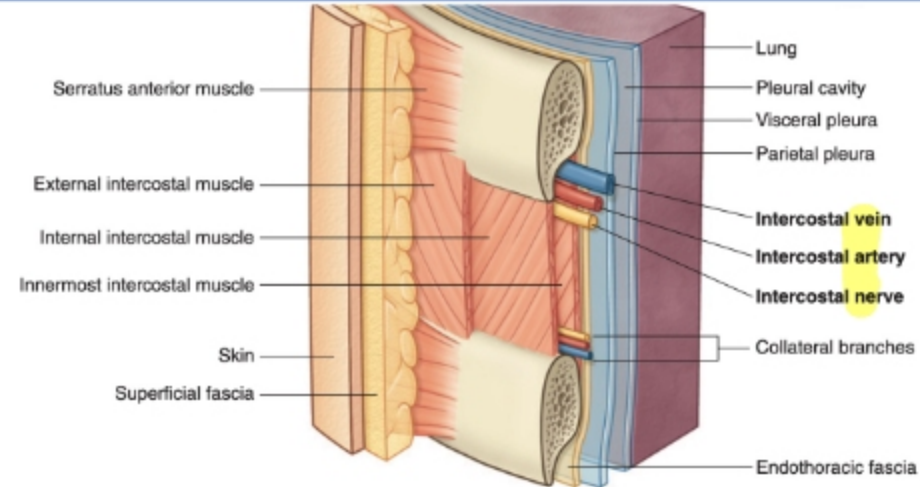
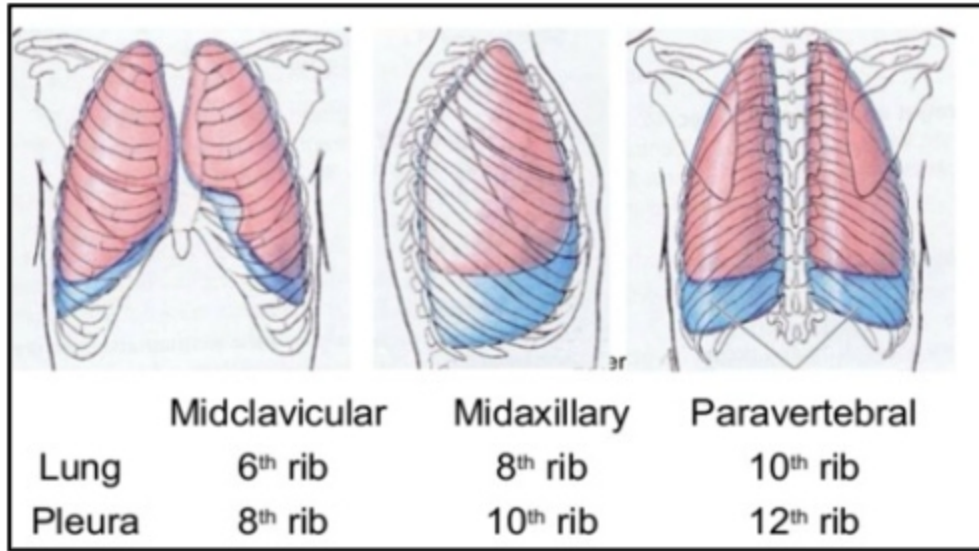
Piercing each crus

Greater and lesser splanchnic nerves

Contact admin

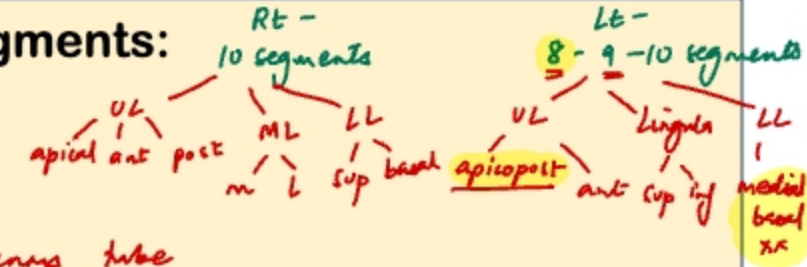
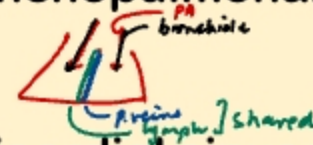Join our group

# Thorax anatomy



Intercostal space VAN except: 1ct - NAV

Bronchopulmonary segments:

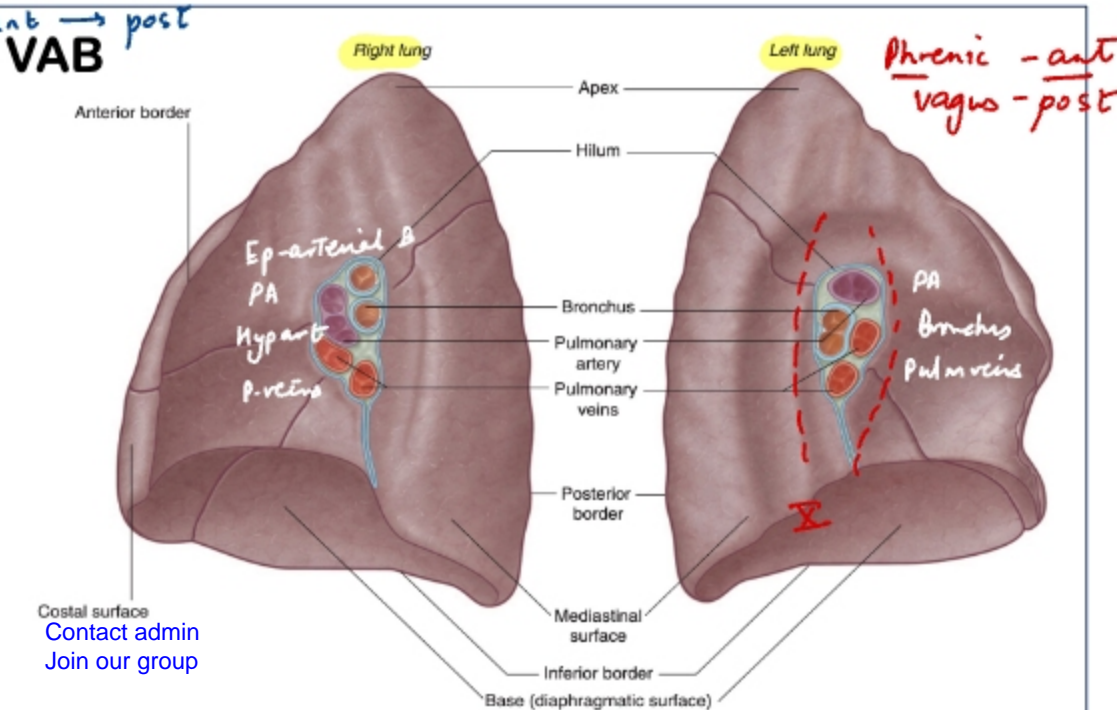


Pericardial sinuses:

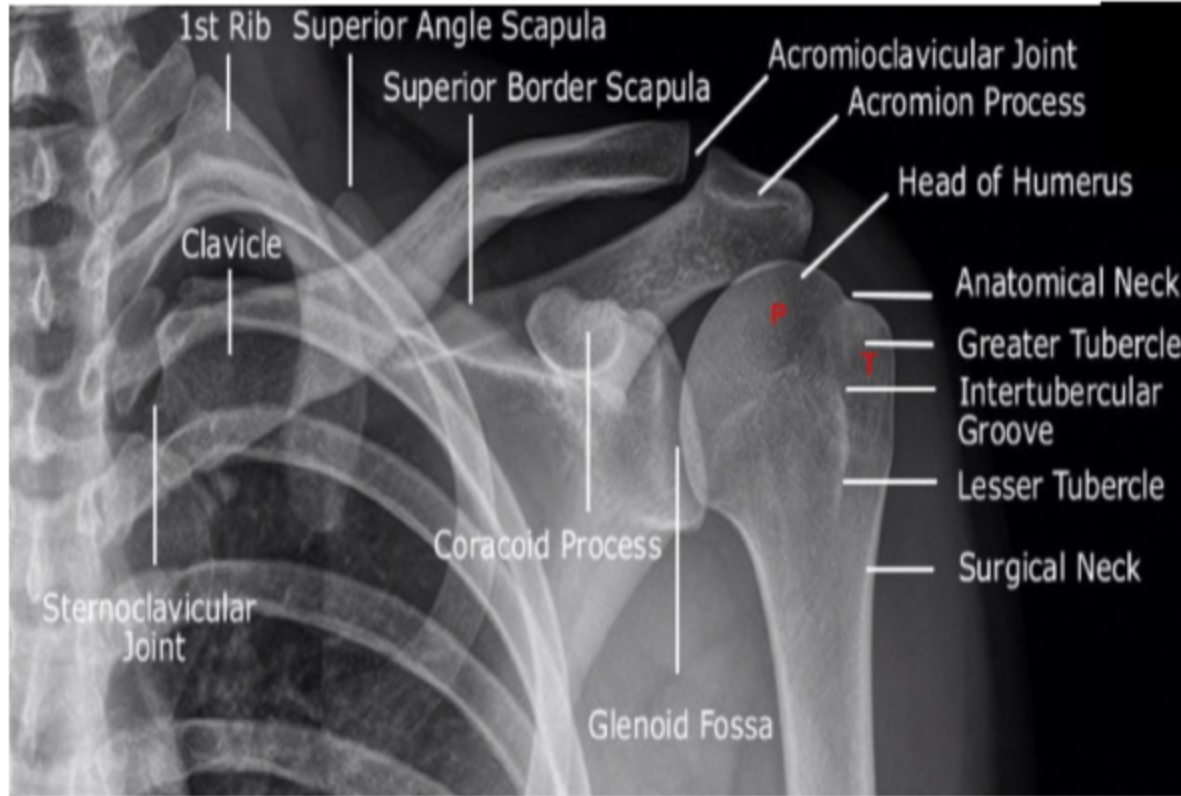
Transverse: arterial (PA/Ao) - venous tube (SVC)

Oblique: Cul-de-sac - behind LA

RT diaphragm higher - Lt hilum higher  
- Lt B higher



# Upper Limb



## CORACOID

Type of epiphyses: *Atavistic*

*long head - supraglenoid*

Origin: Short head of biceps, Coracobrachialis

Insertion: P.minor

**GT:**

S<sub>sp</sub> - 0-15° abd<sup>n</sup> } Suprascap N

I<sub>sp</sub> - } ER } Axillary N

**LT:** Subscapularis - add<sup>n</sup> / IR - Subscapular N

## Intertubercular groove:

Pmj } flexion - LPN/MPN

LD } ADIR } extension - Infracodacal

Tmj } extension - Lower subscap N

## Clavipectoral fascia

Encloses subclavius and P.minor

Pierce - *Thoraco-acromial* LPN *Cephalic vein*

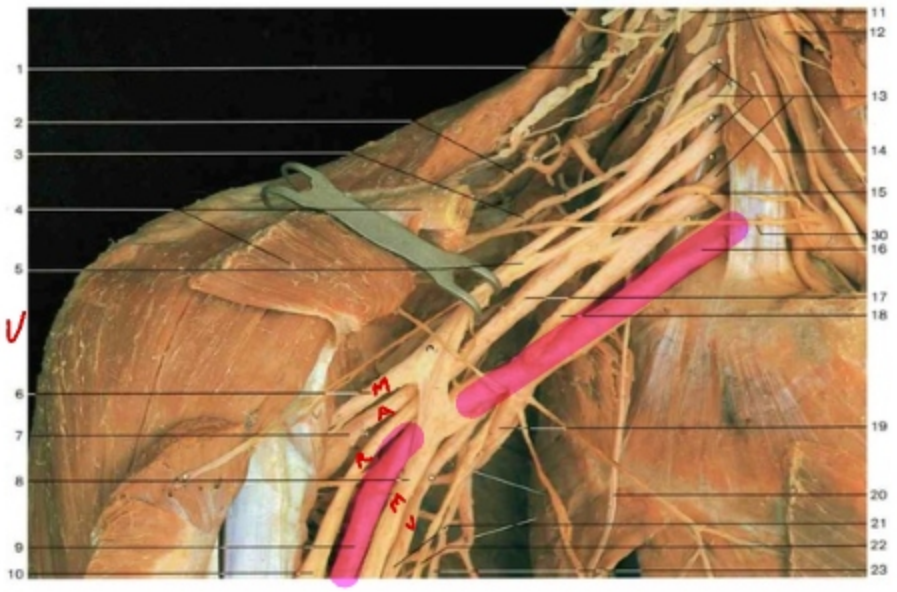
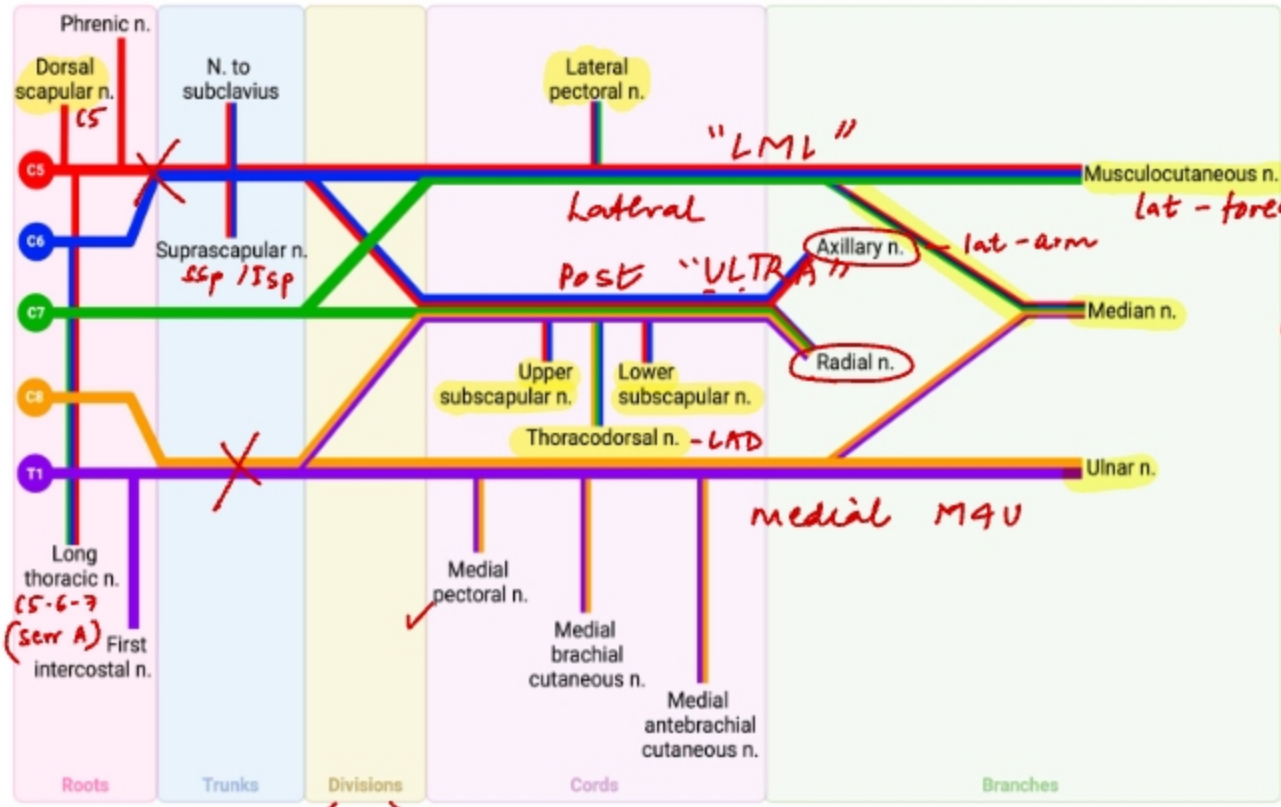
A

Contact admin  
Join our group  
**Pierce P.minor:** *Medial pectoral N*

## Types of epiphysis

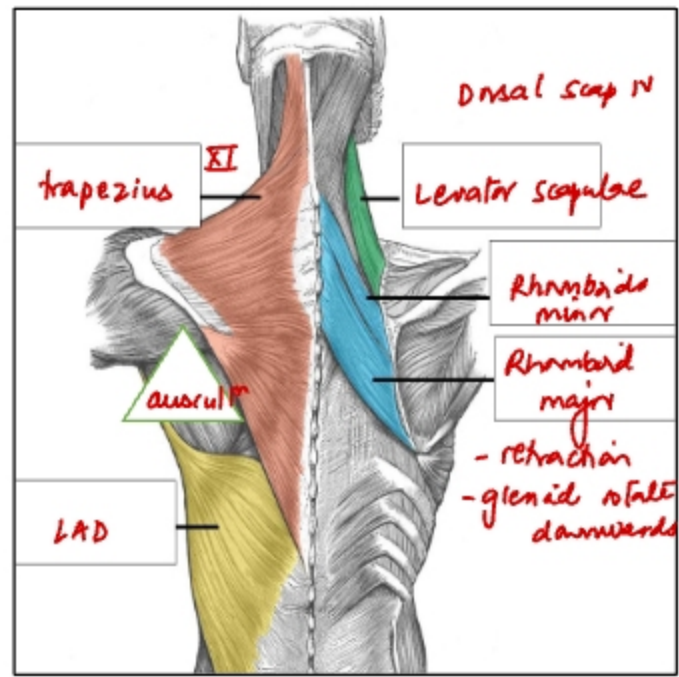
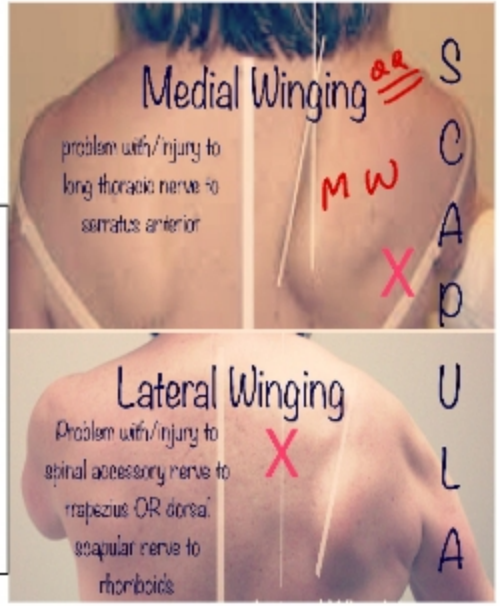
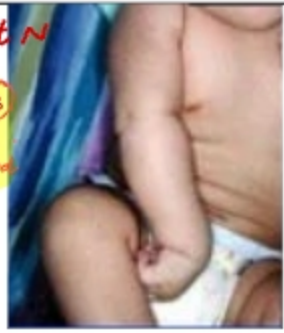Pressure <sup>wt</sup>	Head of femur / humerus, lower end of radius, tibial condyles
Traction	GT, LT of femur, mastoid process, GT and LT of humerus
Atavistic <sup>at</sup>	Coracoid process, Os trigonum
Aberrant	Head of 1 <sup>st</sup> metacarpal, Base of other metacarpals

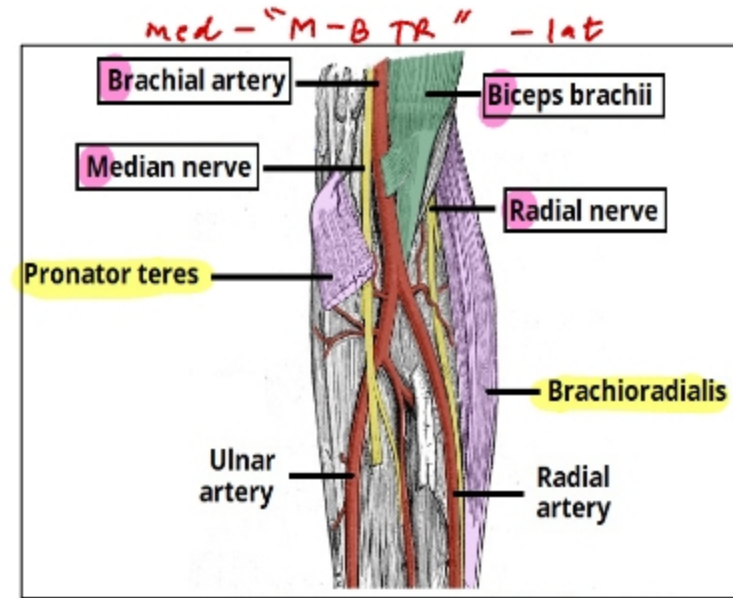
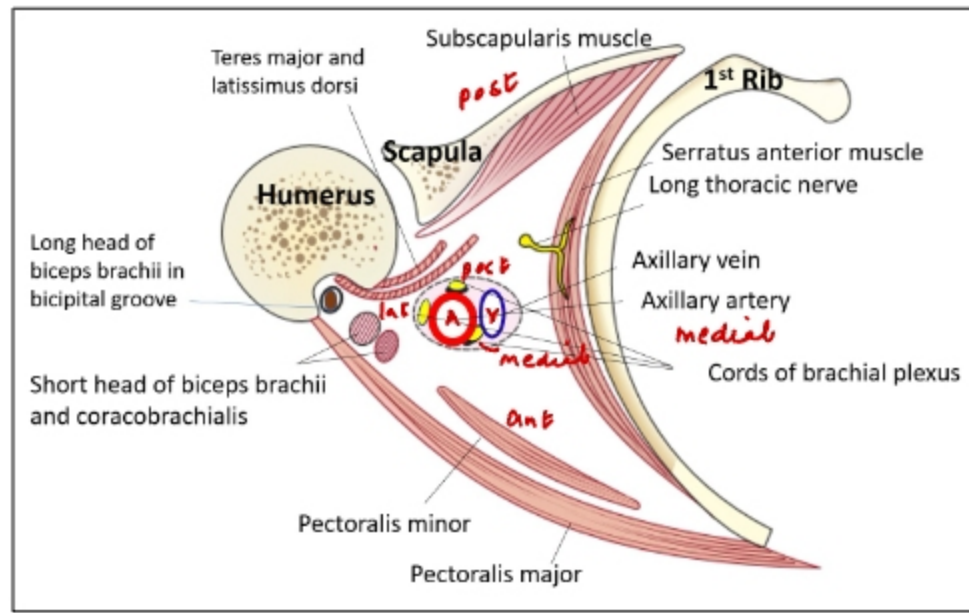
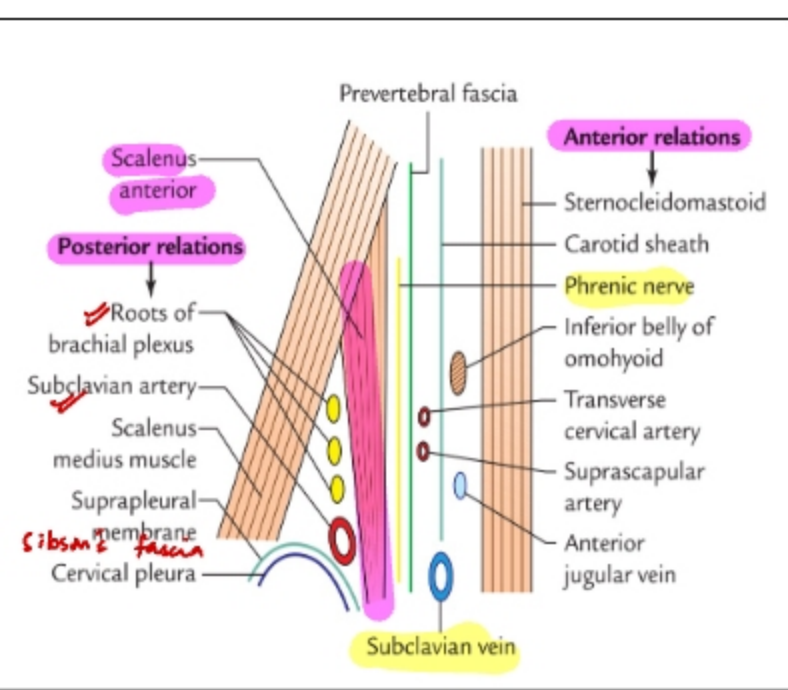
# Brachial plexus



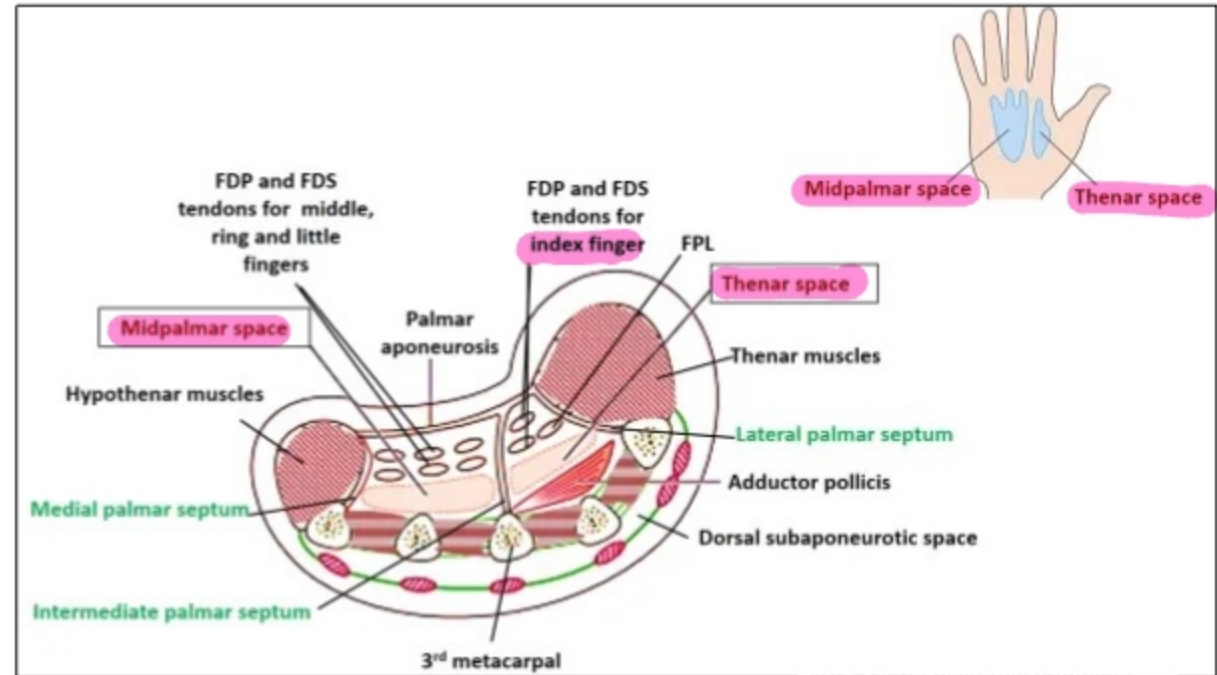
**Upper trunk:** Erb's palsy - Axillary N / musculocut N  
 C5-C6  
 "policeman tip"  
 deltoid 15-90° abd<sup>n</sup> + minor ER  
 brachialis biceps (CB)  
 Flex / elbow supine

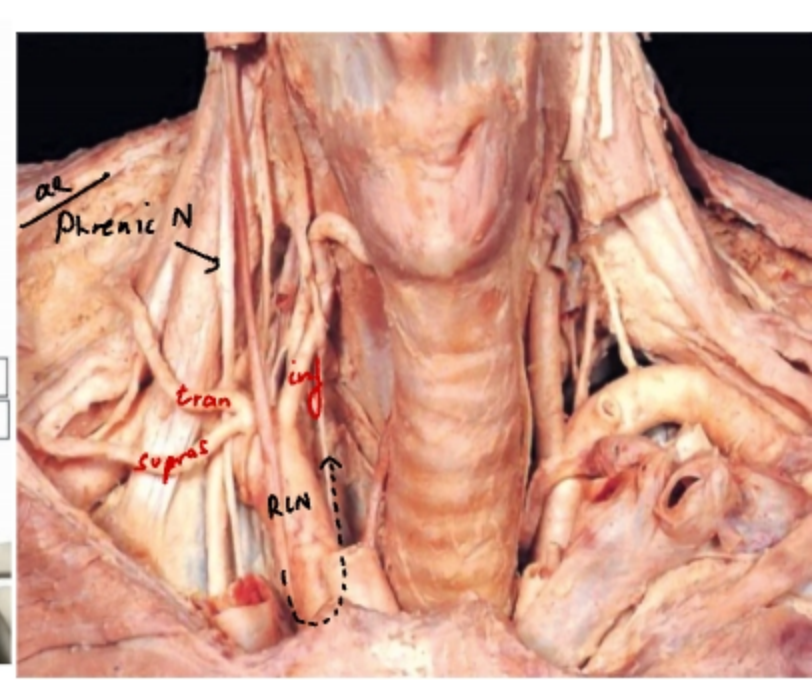
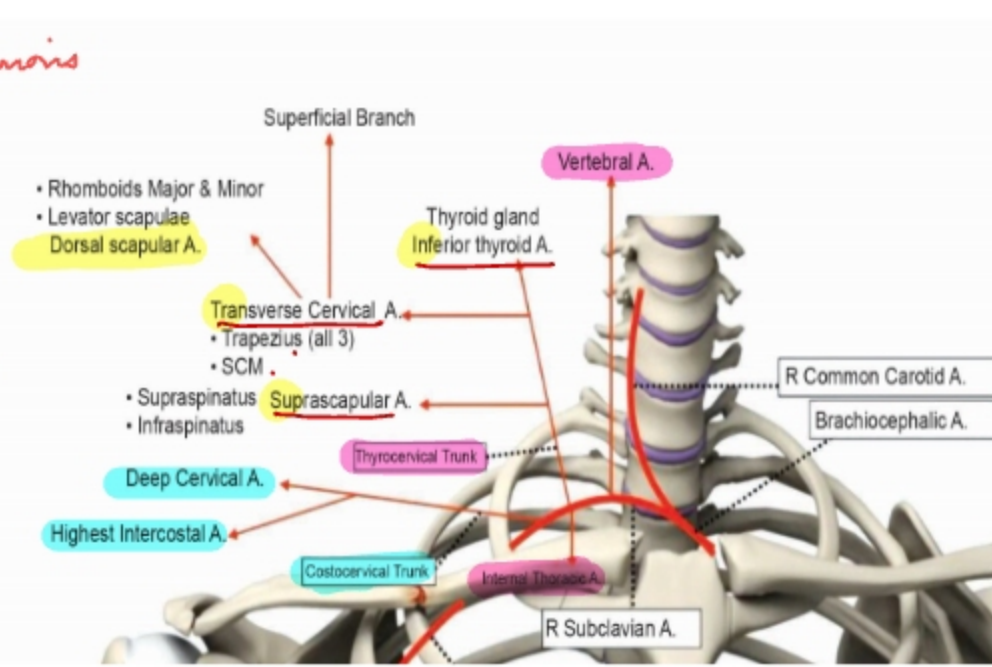
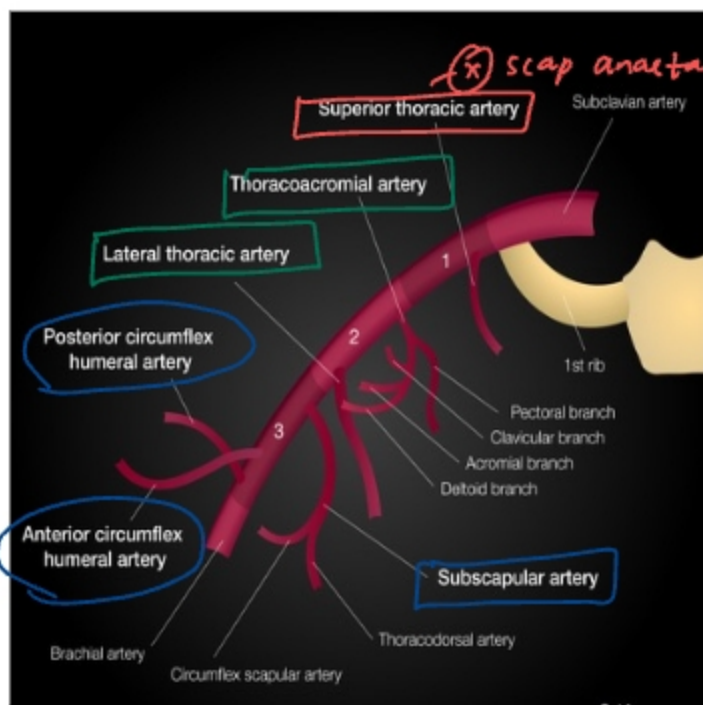
**Lower trunk:** Klumpke's palsy - claw hand  
 (C8-T1)  
 Contact admin  
 Join our group





**Axillary sheath: Continuation of** *prevertebral fascia*  
**Ant to Scalenus anterior:** *SCV / Phrenic N*  
**Inter-scalene triangle:** *SCA / Roots-trunks of BP*

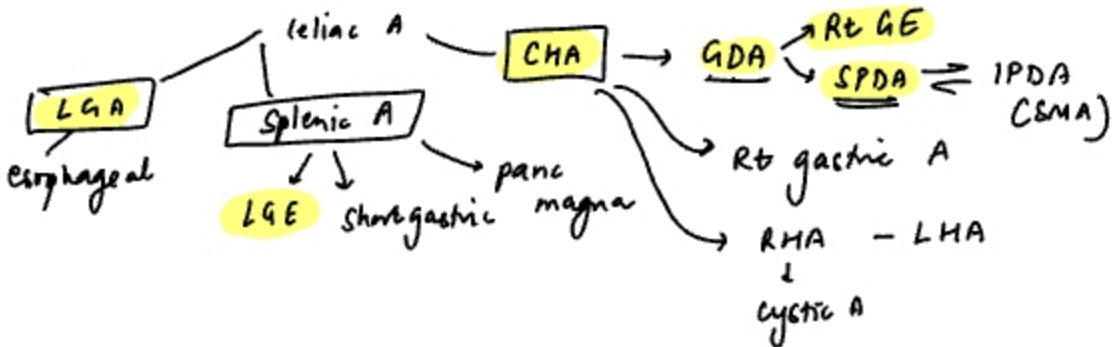
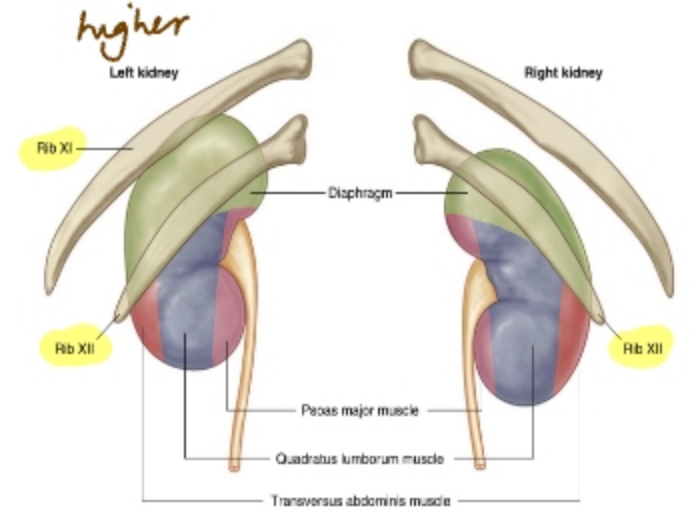
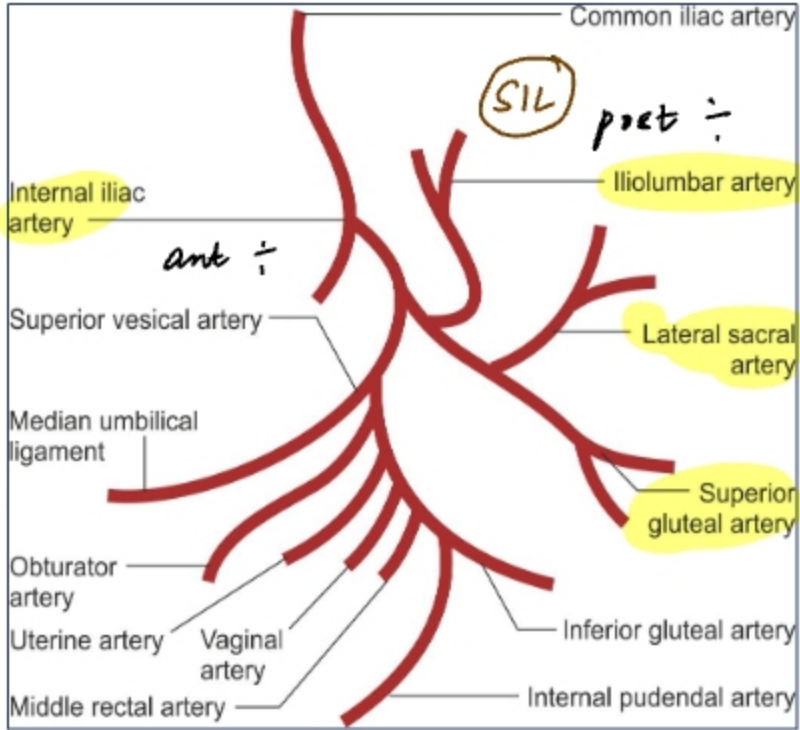
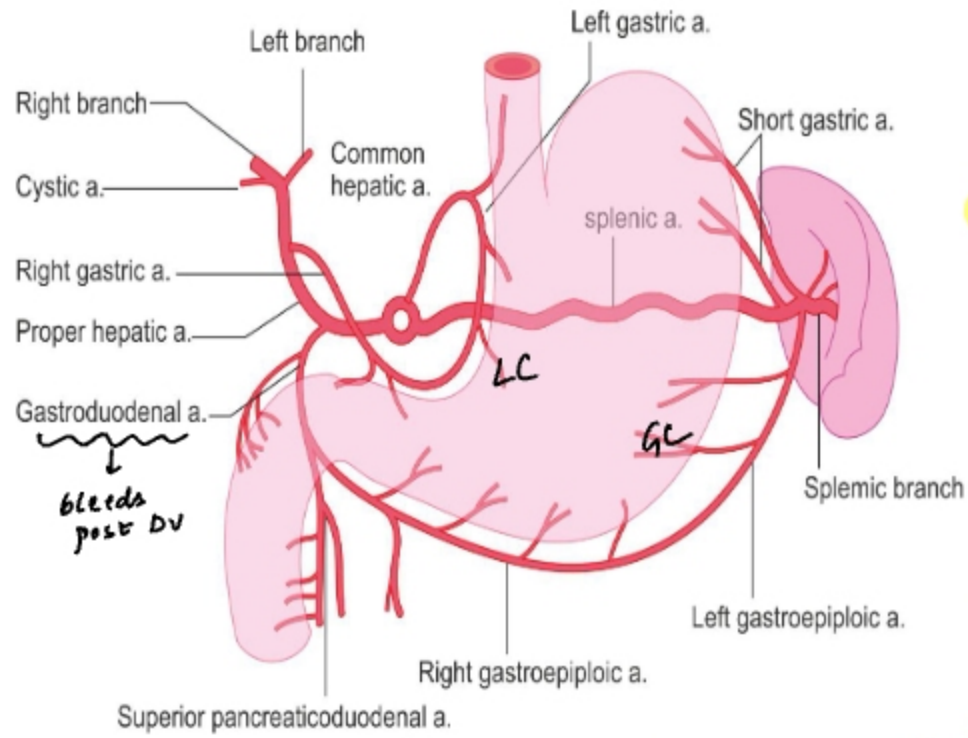




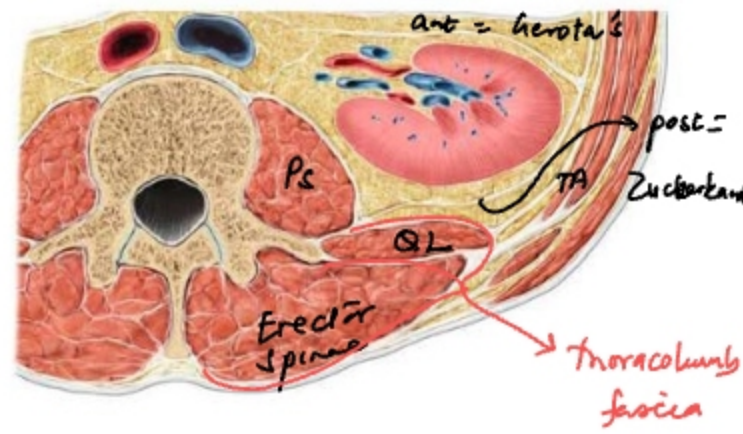
Axillary A - p. minor  
SALT      SPA

Subclavian A  
 V = vertebral  
 C = costocervical  
 D = dorsal scapular

# Abdomen

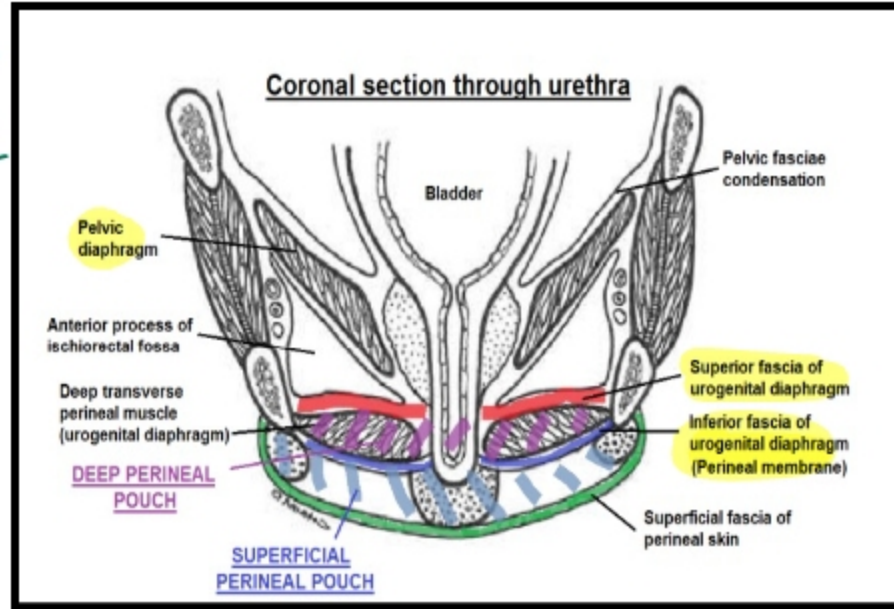
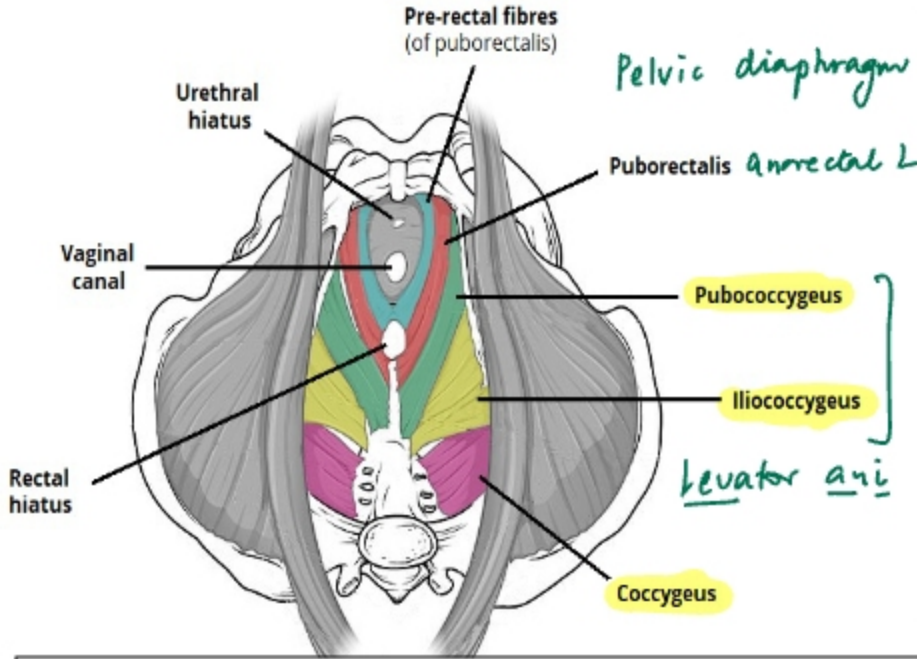


Replaced RHA → SMA  
LHA → Lt gastric A





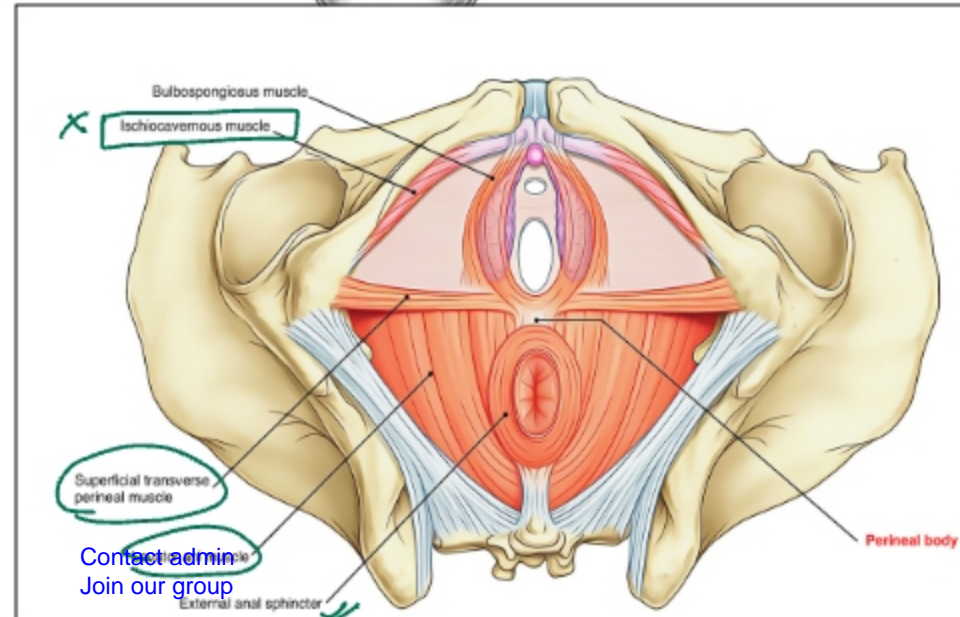
# PELVIS



## Deep perineal pouch:

- Sphincter urethra
- Deep transverse perineal
- Membranous urethra
- Bulbourethral (Cowper's) glands

*↳ \* Bartholin's → sup perineal pouch*



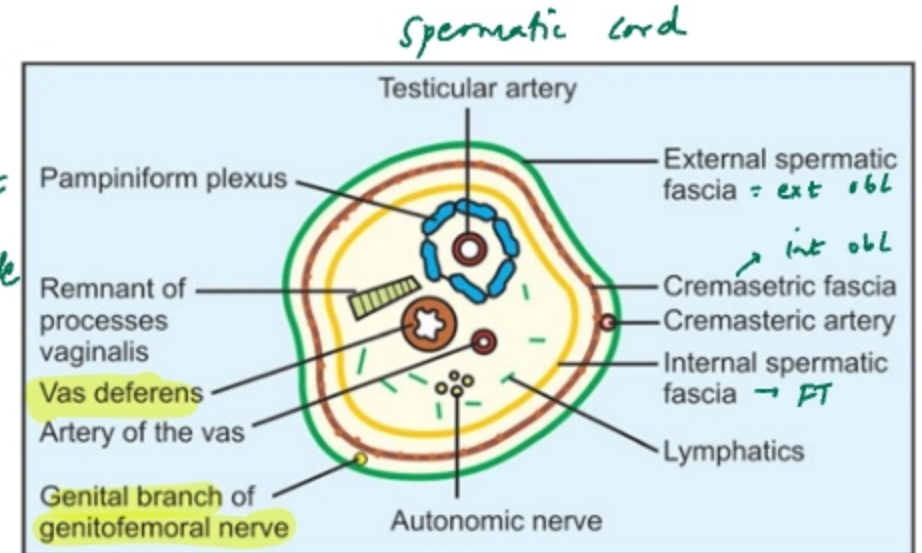
**Perineal body**

4 paired

- Bulbospongiosus
- Sup transverse perineal
- Deep
- Levator ani

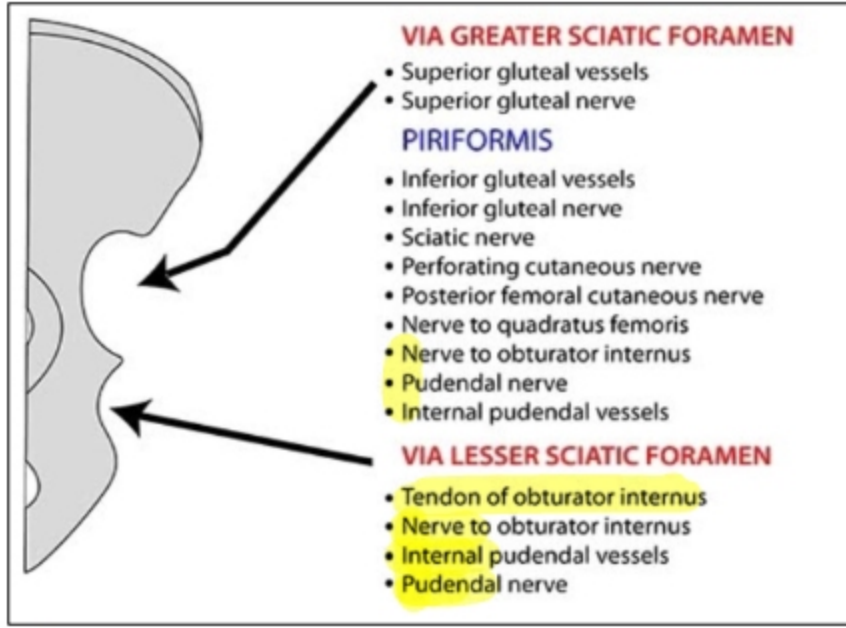
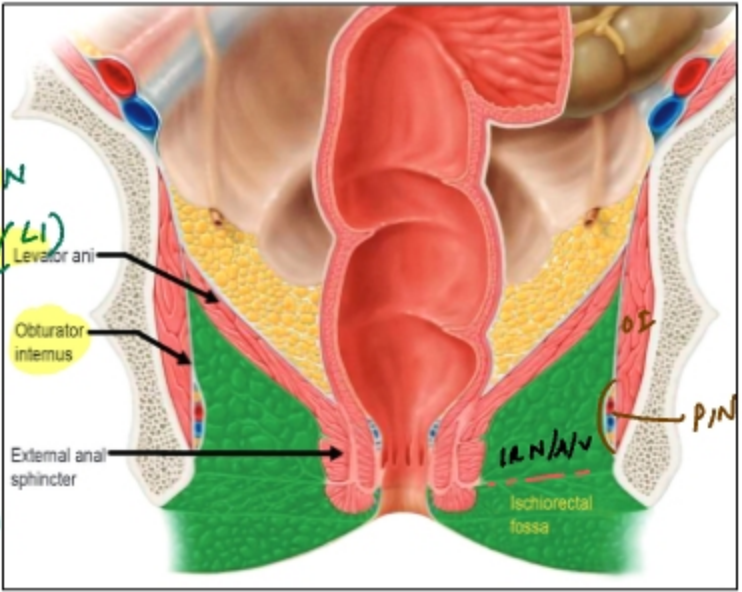
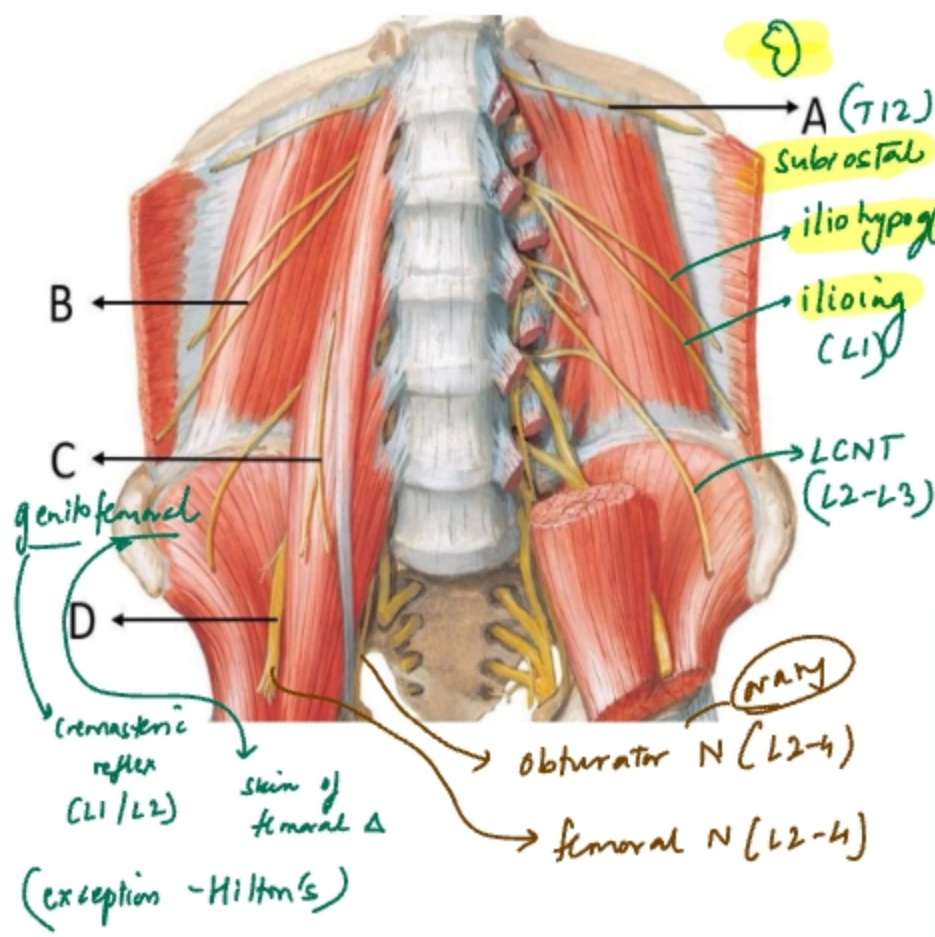
ext anal sphincter

long muscle anal



*OR*  
Iliogastric N → E in inguinal canal (x spermatic cord)

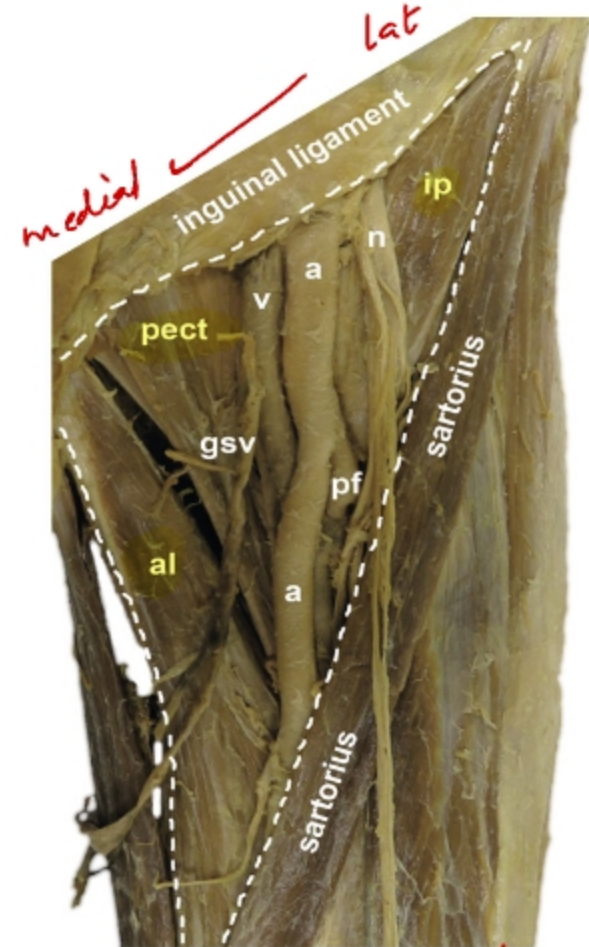
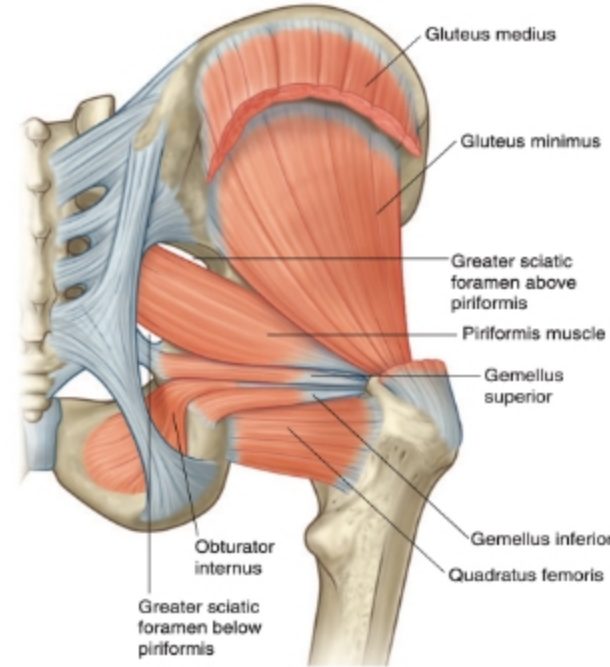
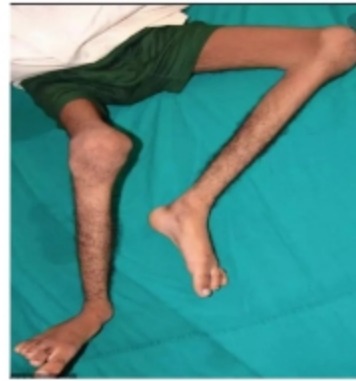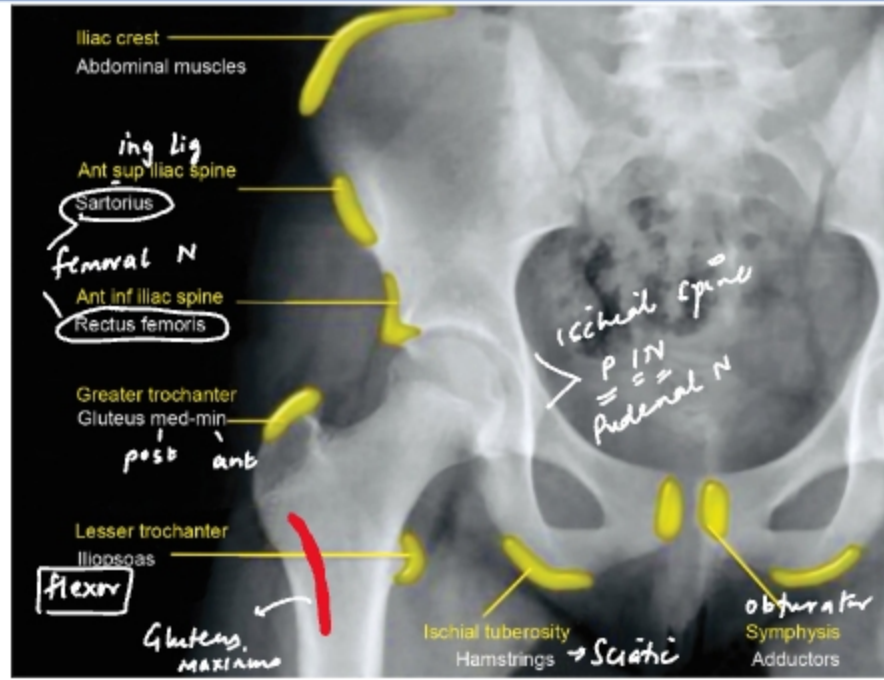
# MISCELLANEOUS



- Contents of Ischioanal fossa:**
1. Pudendal nerve
  2. Internal pudendal vessels
  3. Inferior rectal nerve, vessels → injury &
  4. Posterior scrotal nerves, vessels
  5. Perforating cutaneous N. (S2, S3)

- Structures crossed by root of mesentery:**
- 3<sup>rd</sup> part of duodenum
  - Aorta, IVC
  - Right gonadal vessels, ureter
  - Right psoas/ genitofemoral N
-

# Lower limb



**Gluteus minimus, medius:** Sup gluteal N → TFL  
**Function:** abductors hip + IR hip

**Gluteus maximus:** Inf gluteal N  
**Function:** extensor hip + ER hip

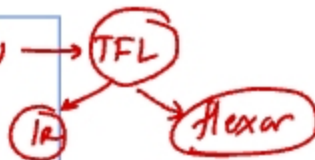**Gover sign**

**Iliotibial tract:** Gl. maximus + TFL

**Contracture:** FABER Hip + FER Knee

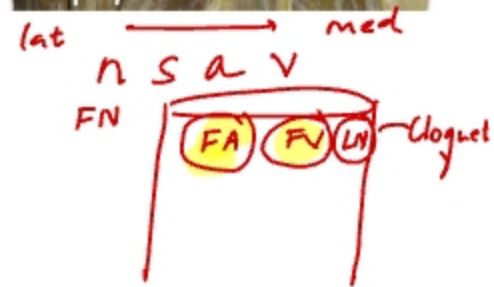**Sartorius:** (tailor's) →

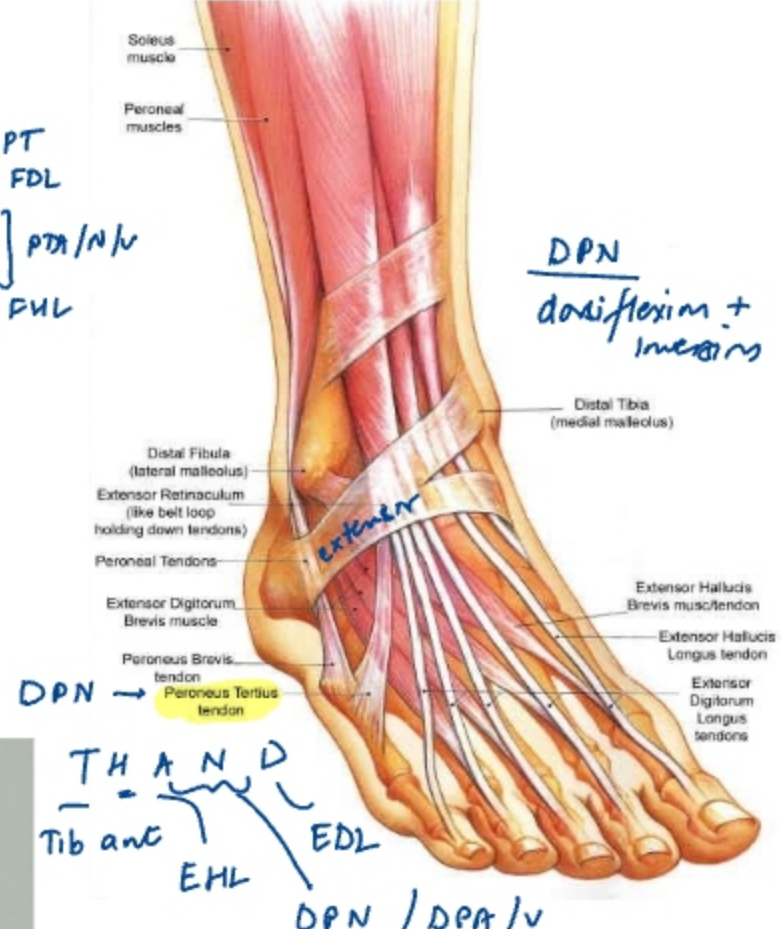
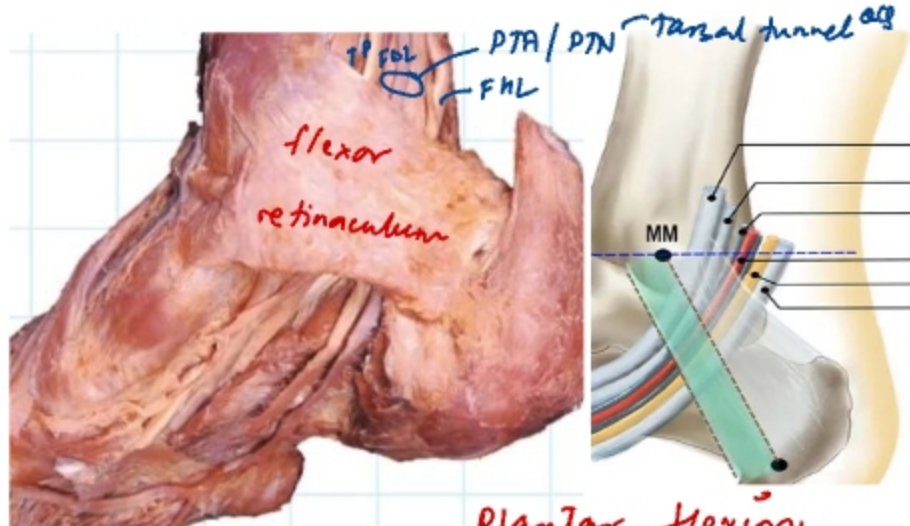
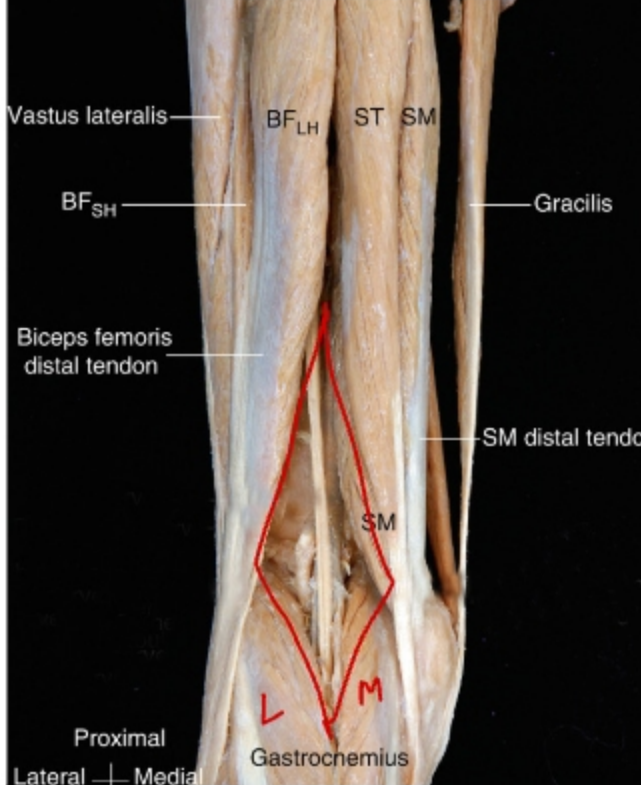
**Rectus femoris:** (Footballer's) → Ext knee + Hip flexion  
 Hamstrings → Knee flexion + Hip extension



**N to OI:** sup gemellus  
**N to QF:** inf gemellus  
**N to piriformis**

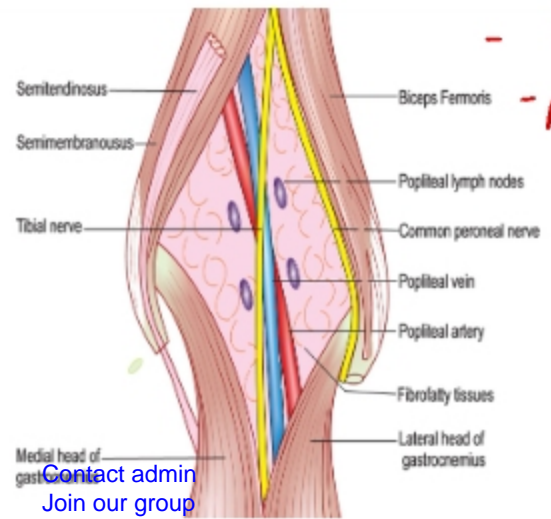
→ ER hip



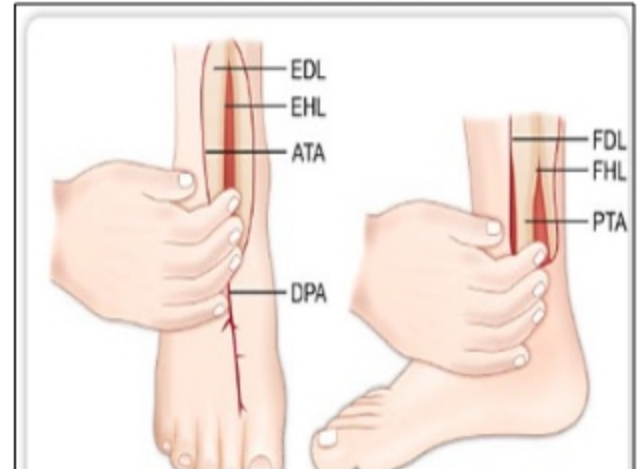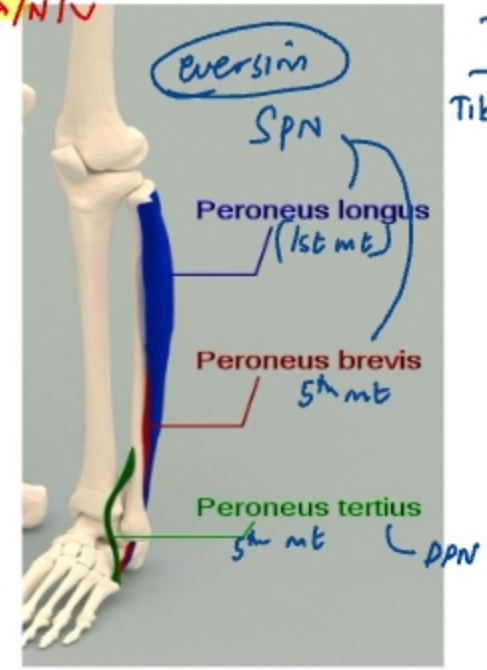


Plantar flexion + inversion  
 Tam Dick & Harry  
 Tib post FDL FHL  
 PTA/N/V

- tibial N / CPN → hooks and neck of fibula  
 - Pop vein  
 - pop artery

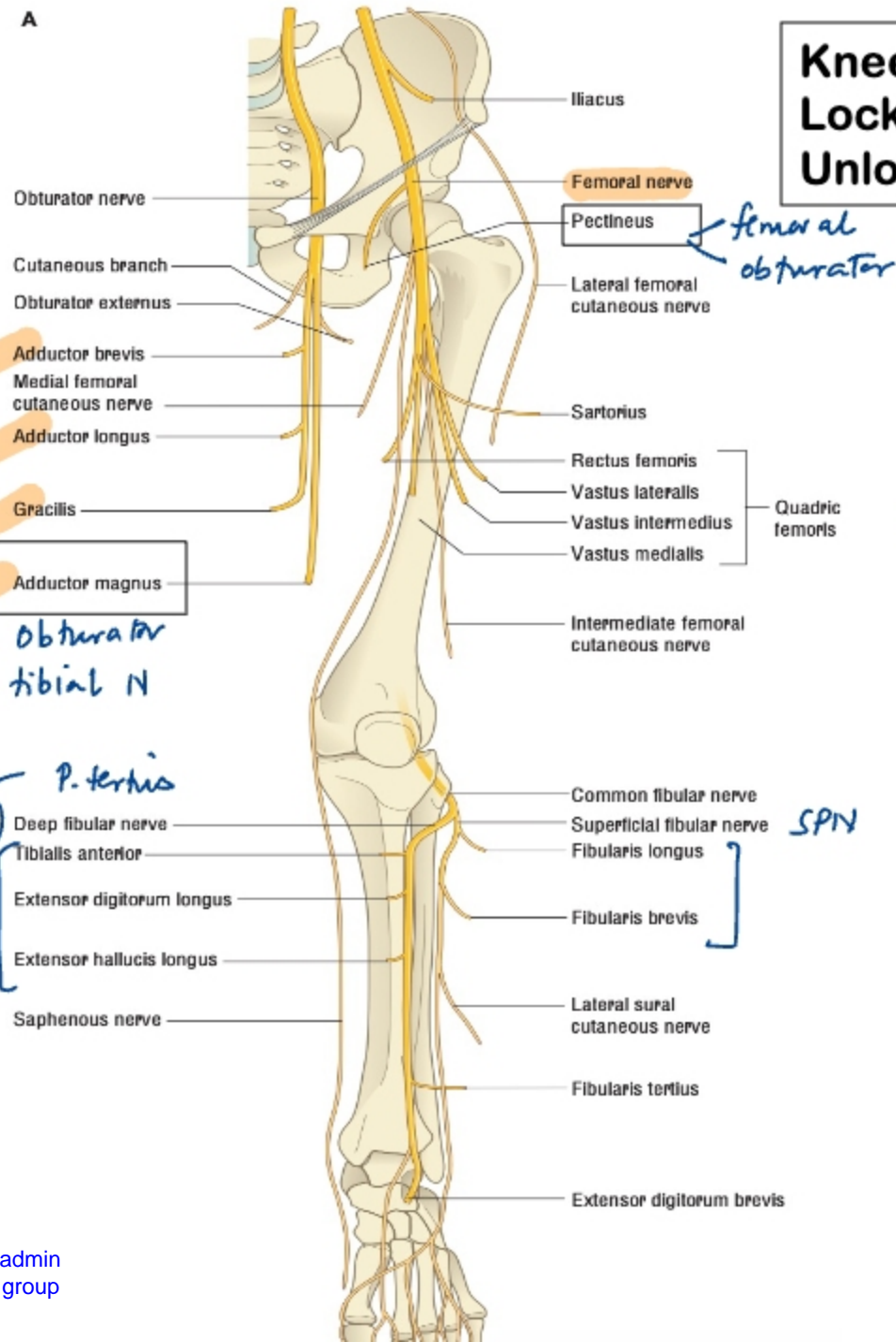


**NERVES of calf:**  
 Anterior (Dorsiflexion + invertor): **DPN**  
 Lateral (Evertor): **SPN**  
 Posterior (Plantar flexion + invertor): **Tibial N**



Contact admin  
 Join our group

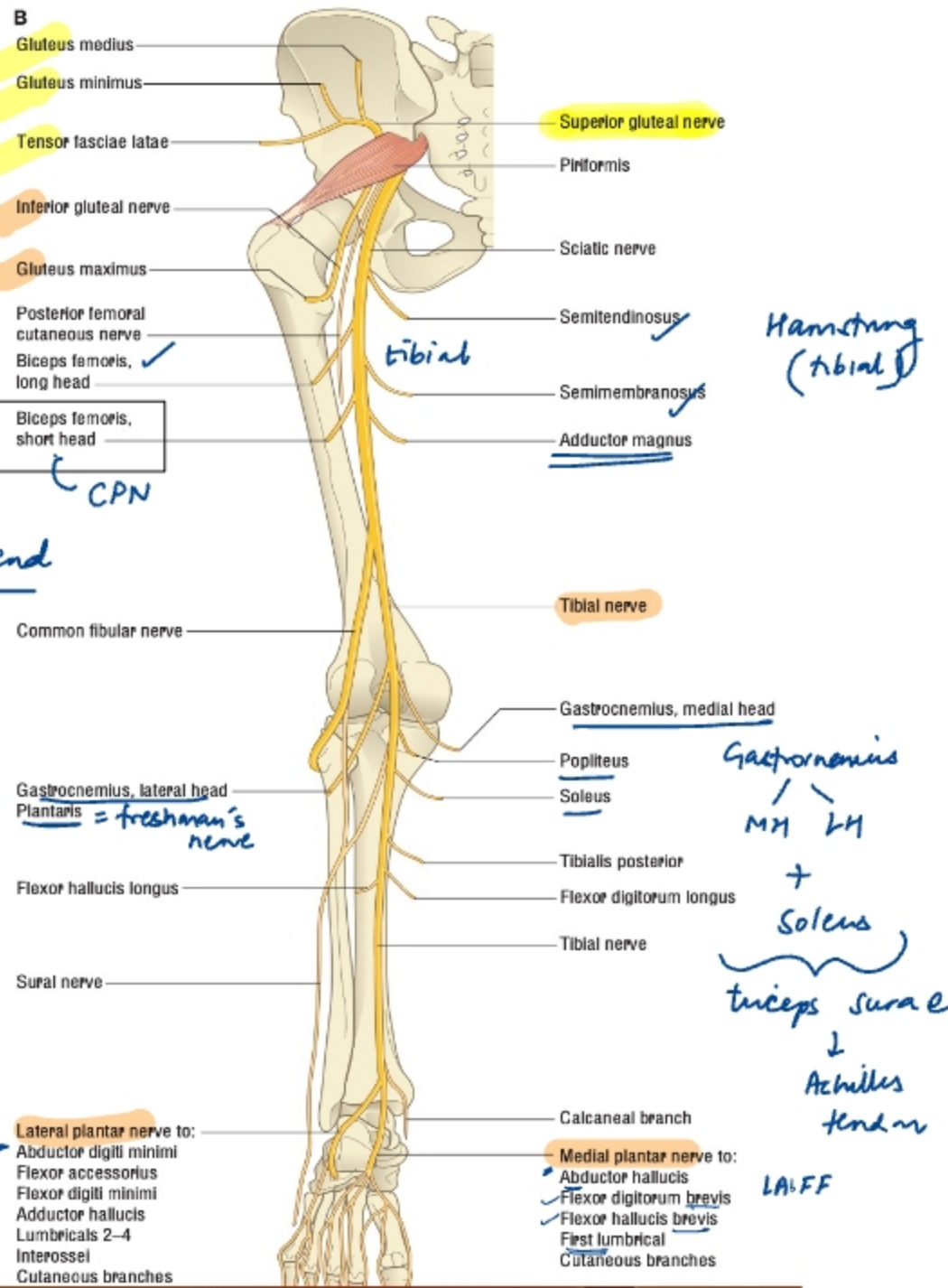
A



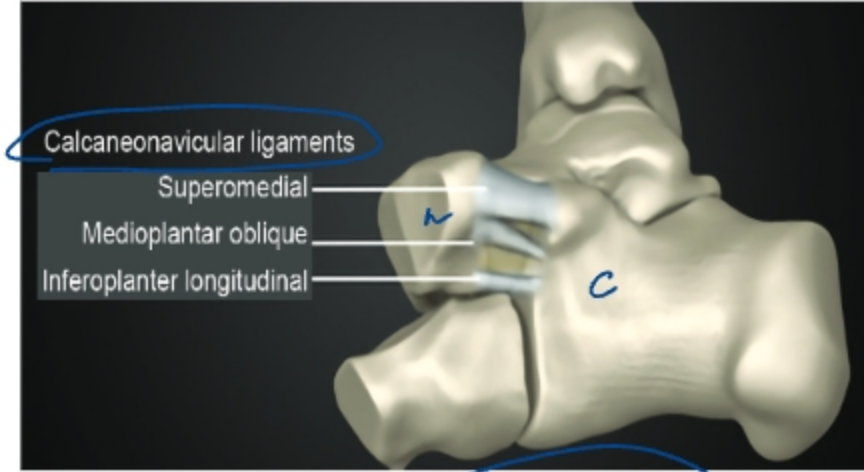
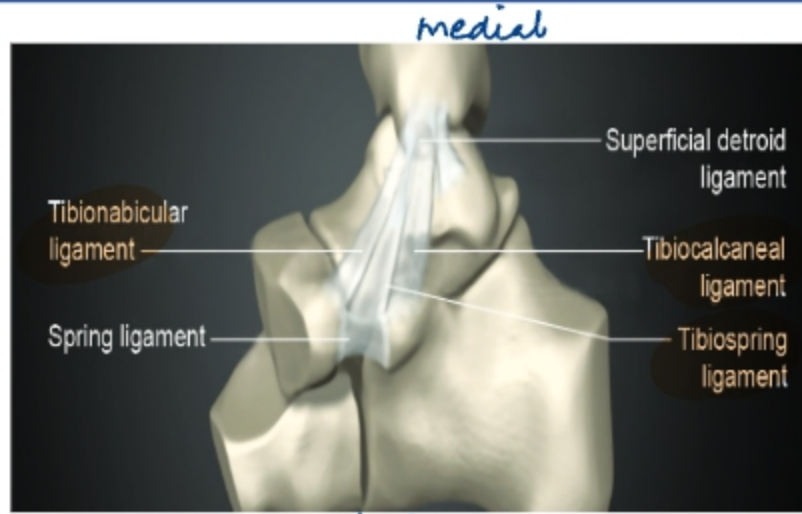
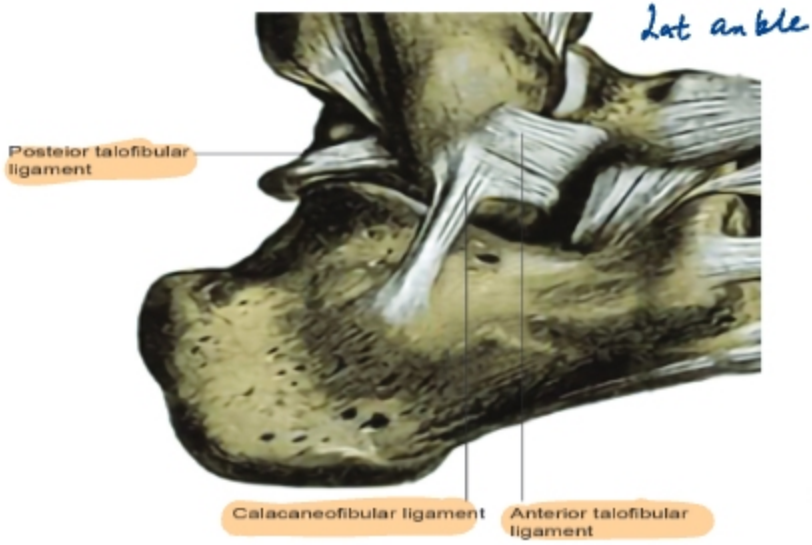
**Knee:**  
**Locking:** *Quadriceps*  
**Unlocking:** *Popliteus*

*Pec Anserinus (Sartorius) gracilis semitend*

B



# Ankle/ Foot



ATFL → C-F L → PTFL  
 (mc lig sprain)  
 Lpl. flexion  
 L inversion — MOI

↓  
 dorsiflexion  
 inversion

↑  
 rare

Deltoid lig — ae / Eversion injury

tibio — NO  
 C  
 talus

Spring lig

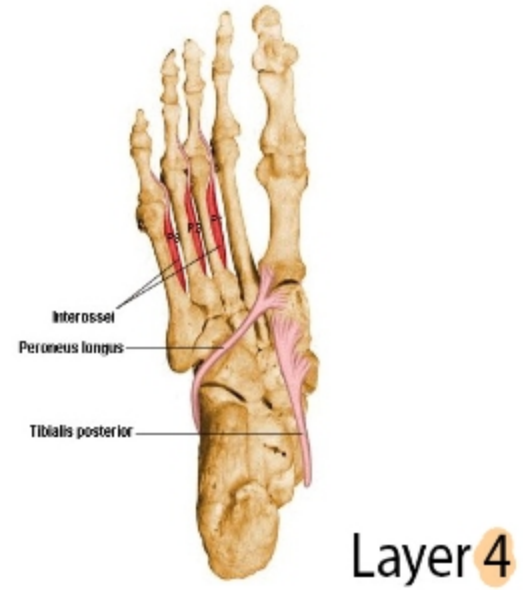
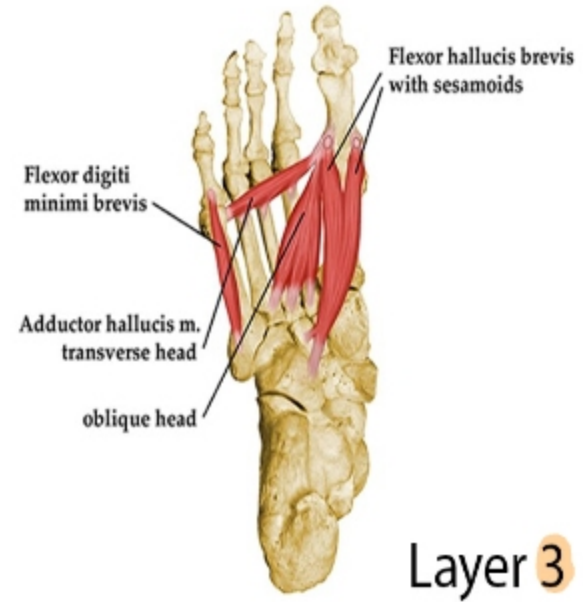
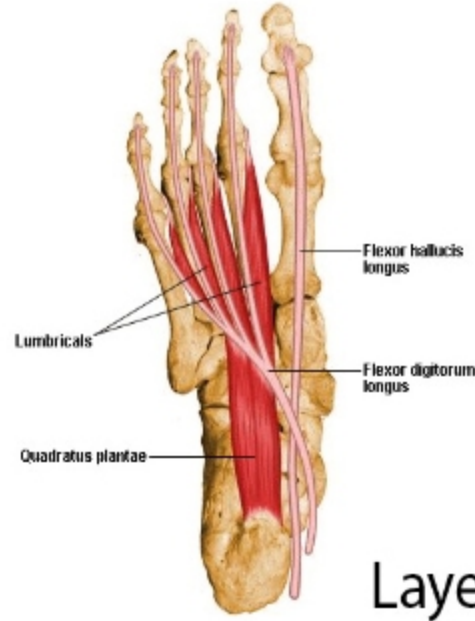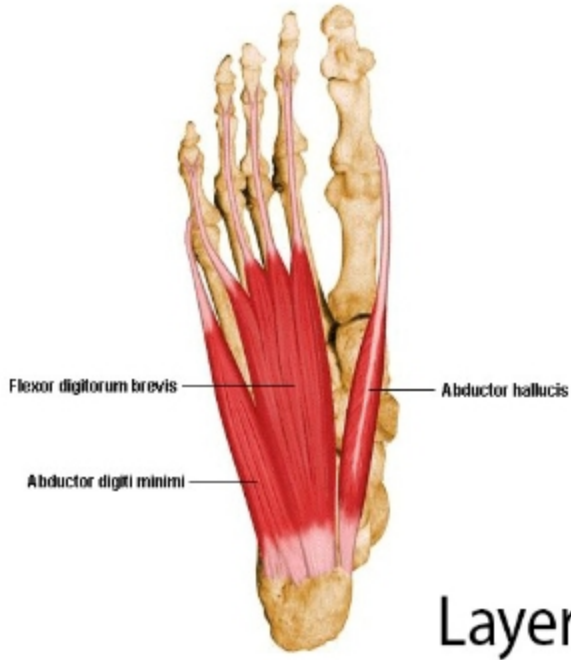'arch'

x

FLAT FOOT

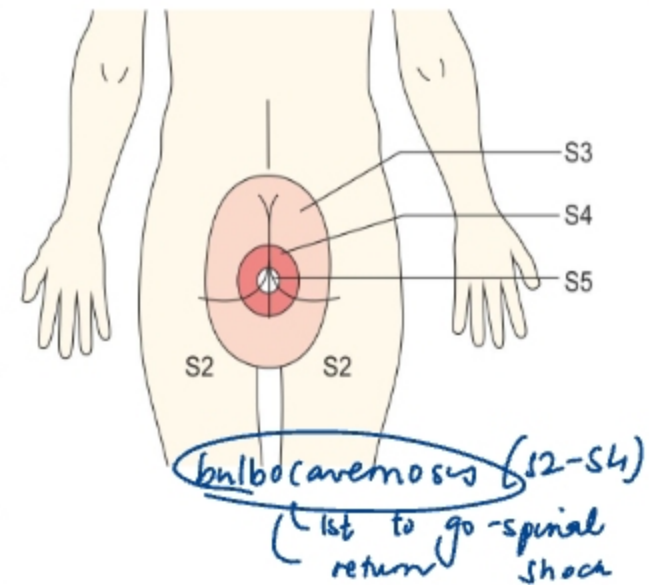
**Bifurcate ligament: Calcaneo-cuboid/ calcaneo-navicular**

# Plantar arterial arch between 3-4

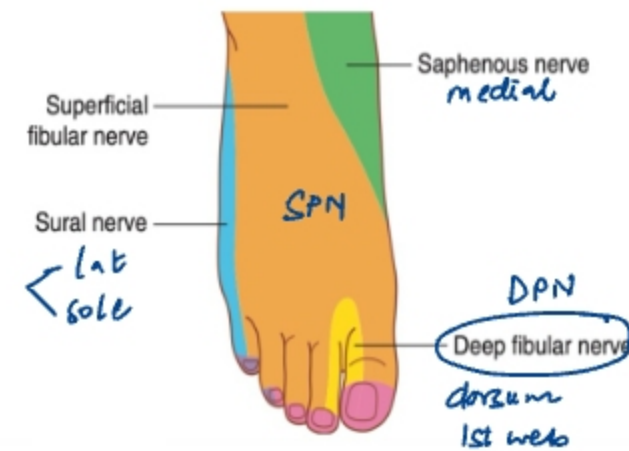


# NERVE ROOTS

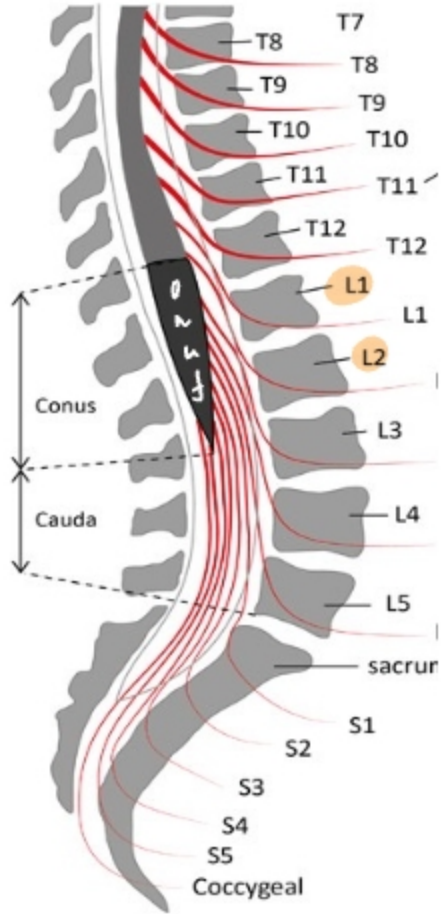
Nerve root	Motor	Sensation	Reflexes
<b>C5</b>	Deltoid	Lateral arm	Biceps (C5/6)
<b>C6</b>	Wrist extensors	Lateral forearm/ Thumb	Brachioradialis (C5/6)
<b>C7</b>	Triceps	Middle finger	Triceps (C6/7/8)
<b>C8</b>	Long finger flexors	Medial forearm/ Little finger	-
<b>T1</b>	Interossei muscles	Medial arm	-



Nerve root	Motor	Sensation	Reflexes
<b>L2</b>	Hip flexion	Anterior thigh, groin	Cremasteric (L1/L2)
<b>L3</b>	Knee extension	Anterior and lateral thigh	Patellar (L3/4)
<b>L4</b>	Ankle dorsiflexion	Medial leg and foot	Patellar (L3/4)
<b>L5</b>	Extensor hallucis longus	Lateral leg Dorsum of foot	-
<b>S1</b>	Ankle plantarflexion	Lateral foot Sole	Achilles (S1/2)



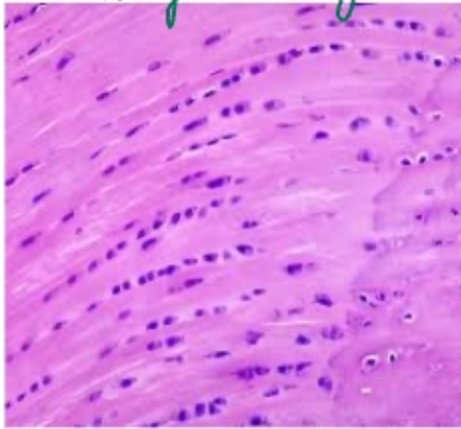
# CAUDA VS CONUS SYNDROME



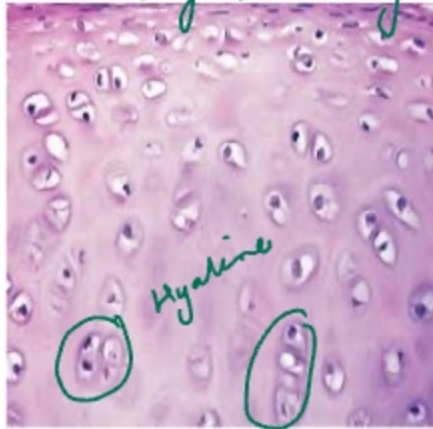
	Conus medullaris syndrome	Cauda equina syndrome
<b>Vertebral level</b>	L1 – L2	L2 – sacrum
<b>Spinal level</b>	Sacral cord segment and roots	Lumbosacral nerve roots
<b>Presentation</b>	<b>UMN + LMN</b> <b>Sudden and bilateral</b> <b>Symmetrical</b> <b>Early incontinence/ impotence</b>	<b>LMN</b> <b>Gradual and unilateral</b> <b>Asymmetric</b> <b>Saddle anesthesia</b>
<b>Radicular pain</b>	Less severe	<b>More severe</b>
<b>Reflexes</b>	<b>Ankle jerks affected</b>	<b>Both knee and ankle jerks</b>

# HISTOLOGY

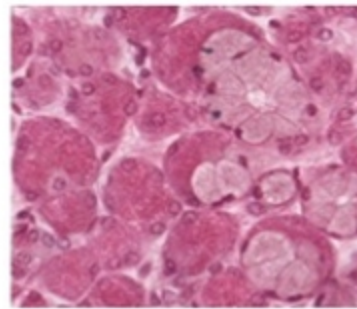
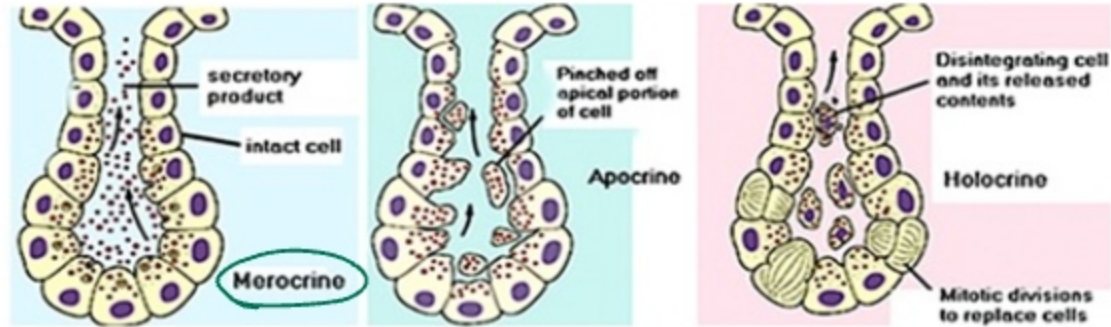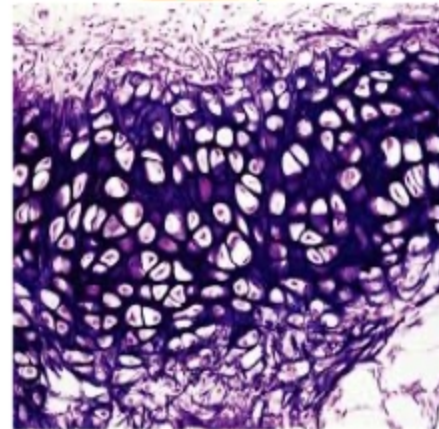
**Fibrocartilage (coll I)**  
 - ⊗ perichondrium  
 - row of chondrocytes



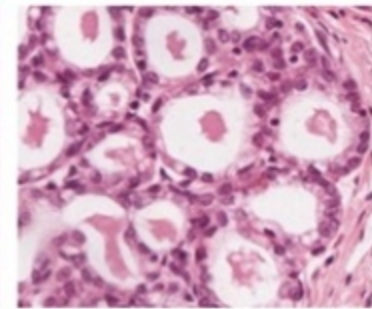
**Hyaline (coll II)**  
 ⊆ perichondr (art cart)  
 nests of chondrocytes



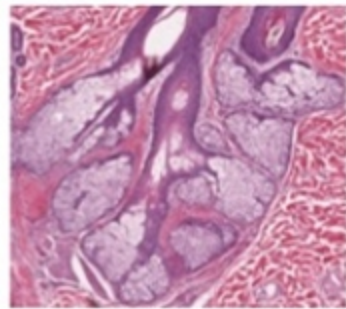
**Elastic**



Submandibular gland  
 Mixed serous - mucinous



Mammary gland

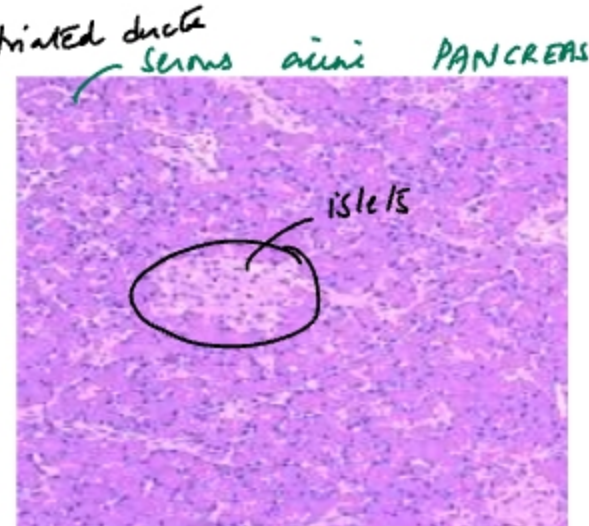
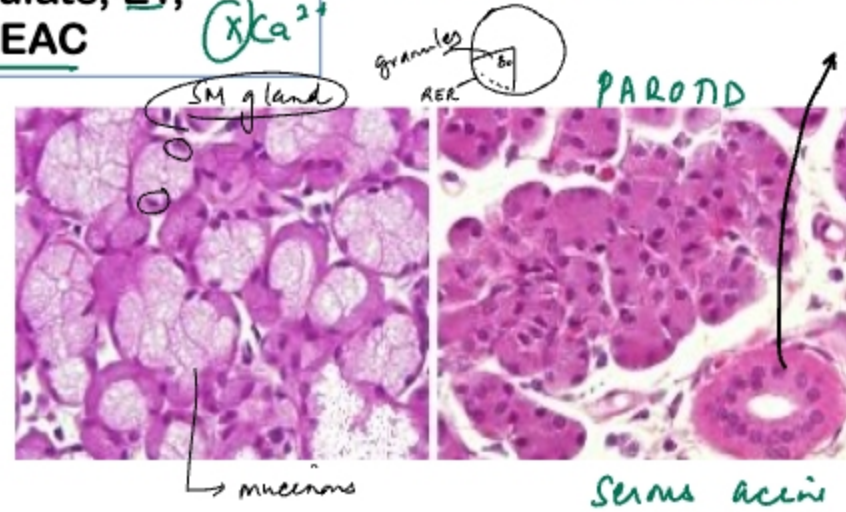


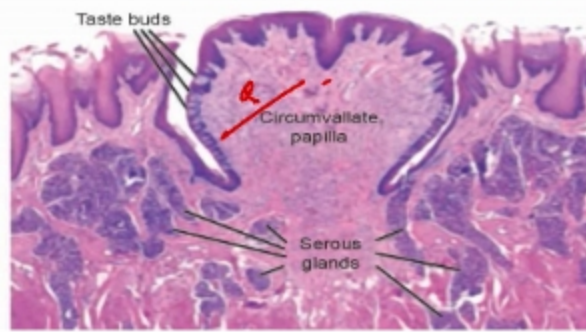
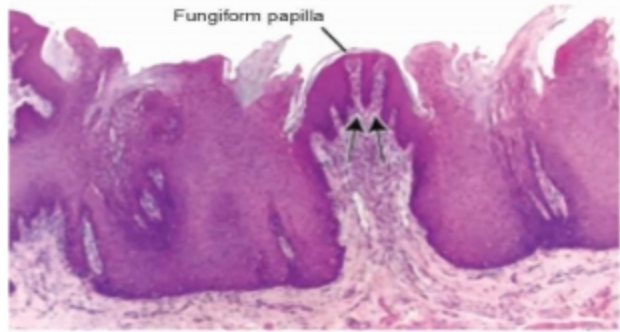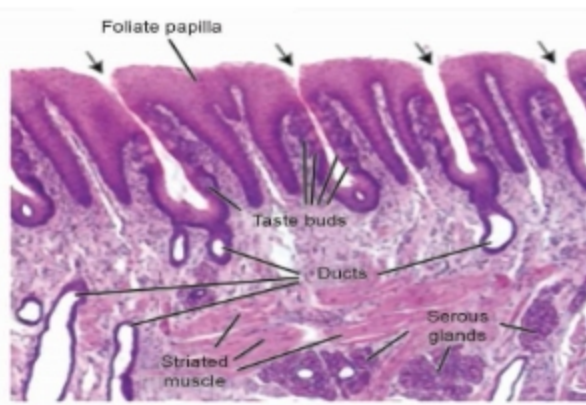
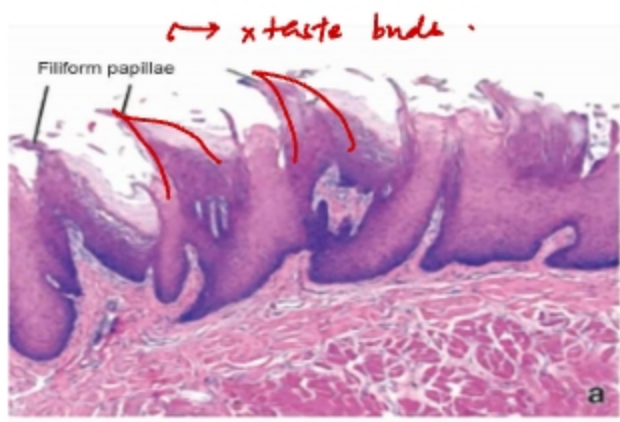Sebaceous gland

IVD, symphysis, Labrum, articular disc, menisci

**Cricoid, thyroid, arytenoid (except apex), trachea articular**  
 ⊆ Ca<sup>2+</sup>

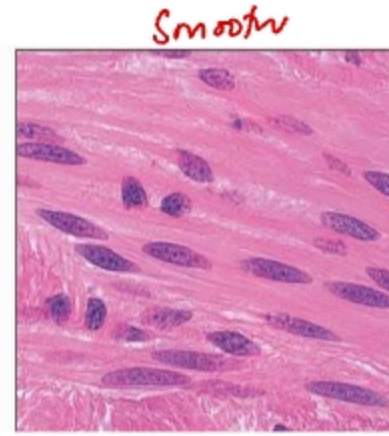
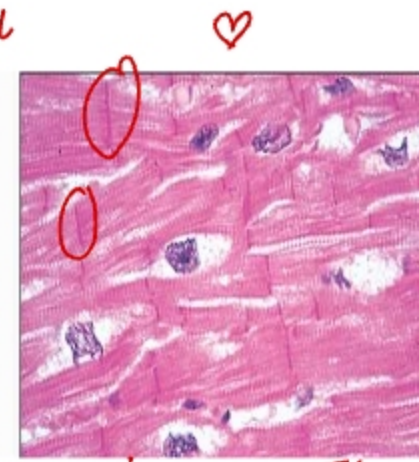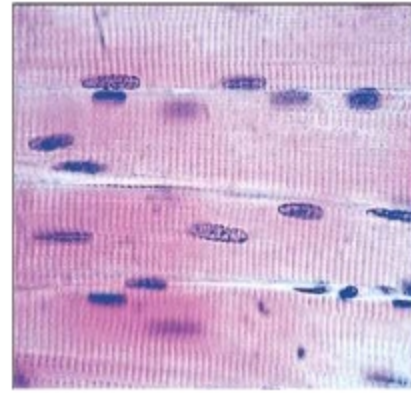
**Epiglottis, Cuneiform (apex), Corniculate, ET, Pinna, EAC**  
 ⊆ Ca<sup>2+</sup>



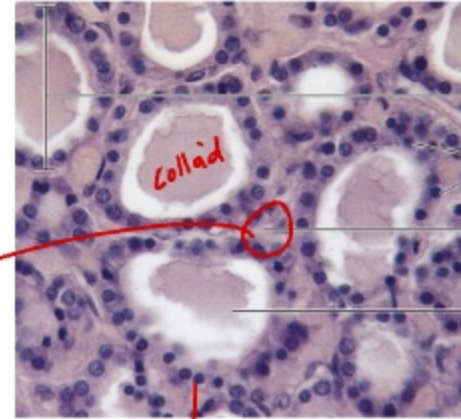

largest

Striated = skeletal



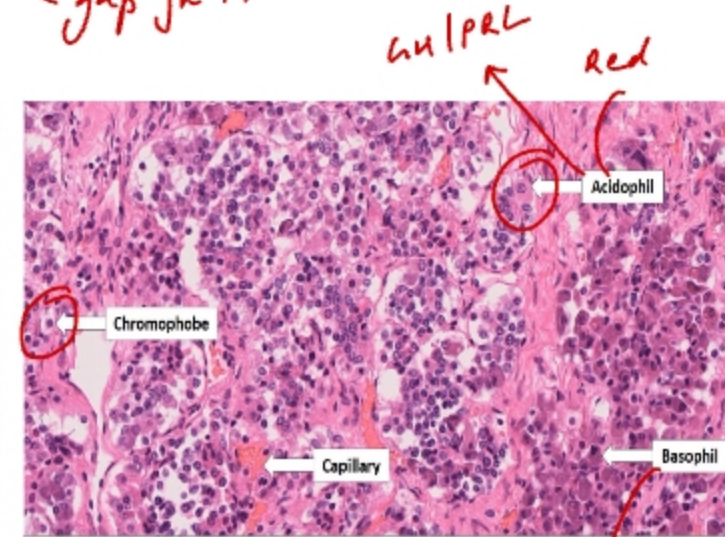
intercalated disc  
(gap in TT)



Parafollicular C-cells

subnodal epitv

THYROID



Pit gland

blue

## GIT

-Mouth, Tongue, Tonsil, esophagus:

*NK stratified squamous*

Filiform papilla: *keratinised str squamous* → HP/gingiva

-Stomach *simple columnar + mucous glands*

-SI → Simple columnar + villi ← GB

Duodenum: Broad villi, Brunner gland

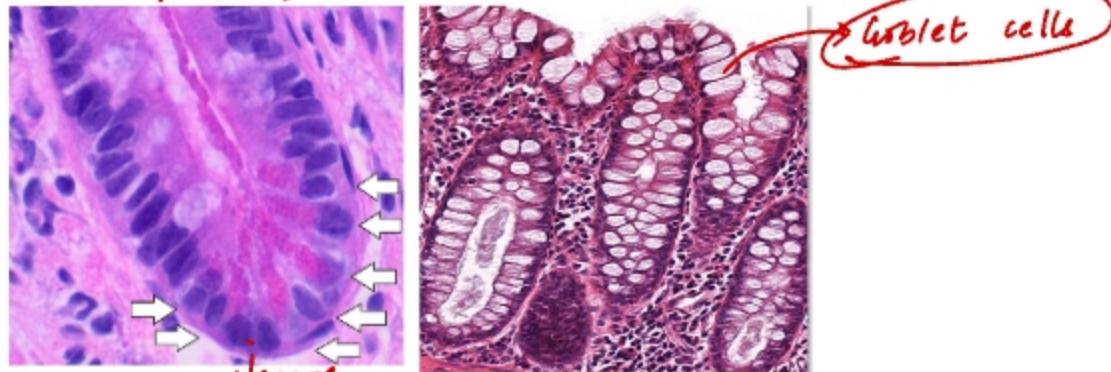
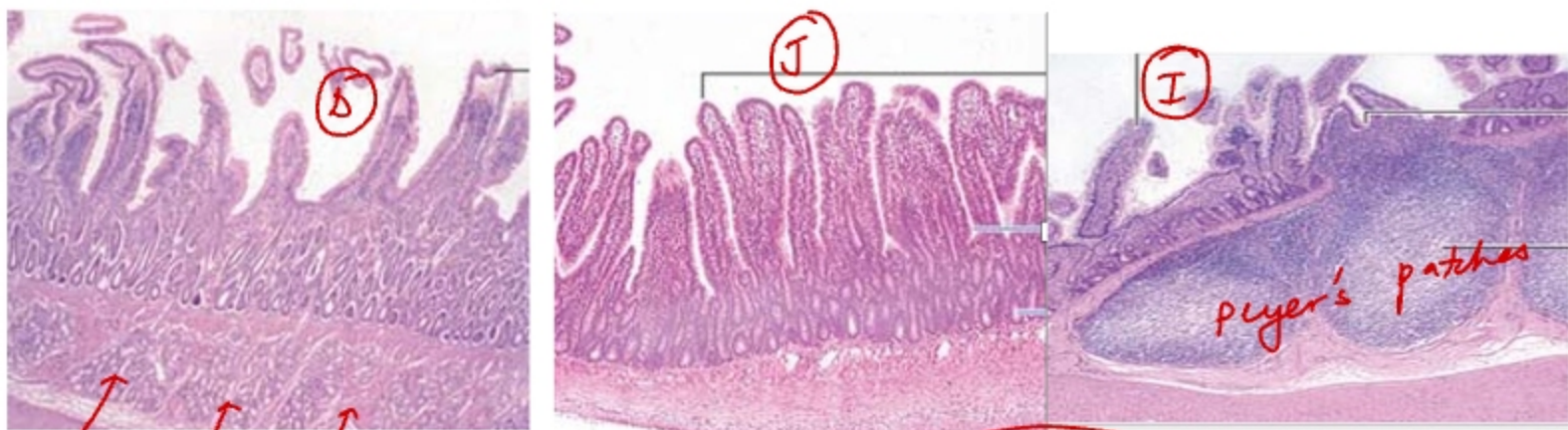Jejunum: Tongue shaped villi

Ileum: Flat villi, Peyer patches

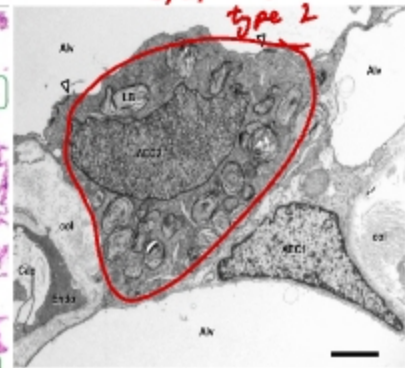
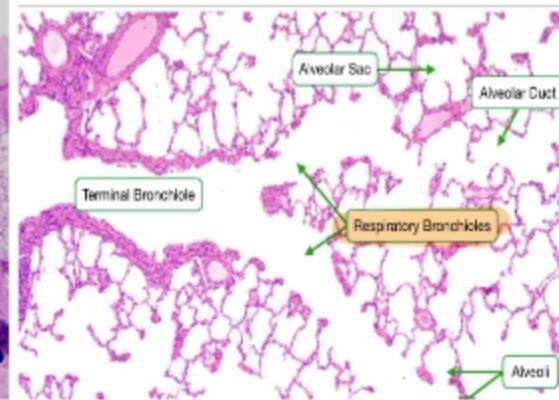
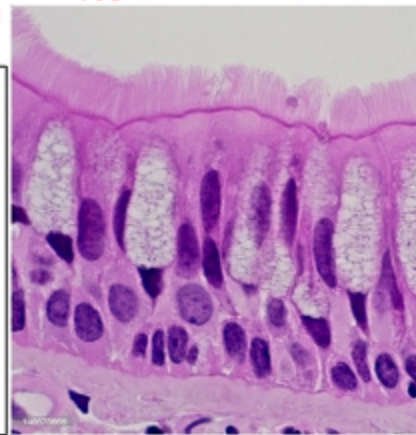
-LI *Simple columnar + Goblet cells*

-Anal canal : Above PL → *columnar*

Below PL → *str squamous.*



*Paneth cells, Ls immune ⊕*



## Respiratory tract

-PNS, Trachea, Bronchus, Proximal bronchiole:

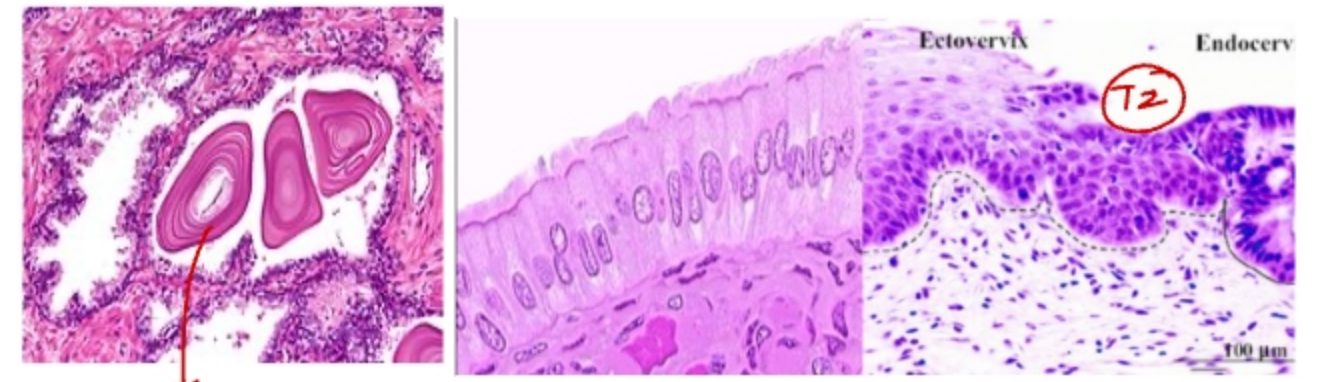
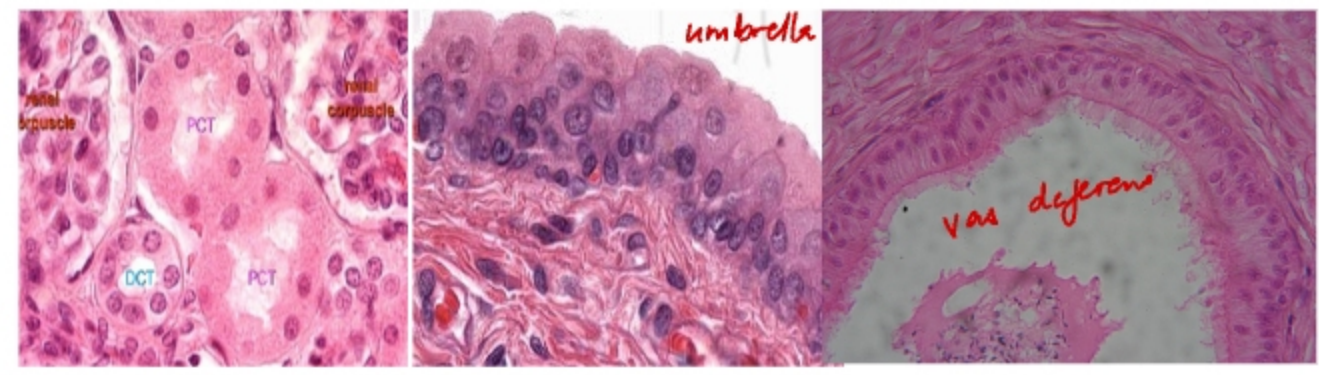
*pseudostratified ciliated columnar*

-Terminal bronchiole: *ciliated columnar*

-Respiratory bronchiole *simple columnar / cuboidal*

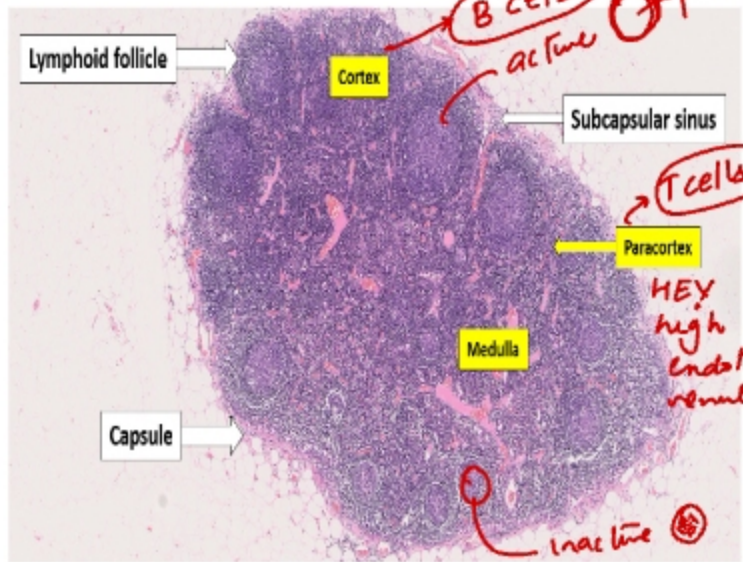
-Alveolus *simple squamous*

- Uro-genital tract** → brush border / "leaky" tight jn
- PCT, DCT - simple cuboidal + "tight" tight jn
  - Calyces, Ureter, UB, Prostatic urethra: transitional <sup>sq</sup>
  - Membranous, penile Urethra: stratified columnar
  - Epididymis, Vas deferens- pseudost columnar + stereocili <sup>sq</sup>
  - Prostate- pseudost columnar + CA stereocili <sup>sq</sup>
- 
- Ovary- simple cuboidal
  - Fallopian tube- ciliated columnar
  - Uterus, endocervix- simple columnar
  - Ectocervix, Vagina- stratified squamous

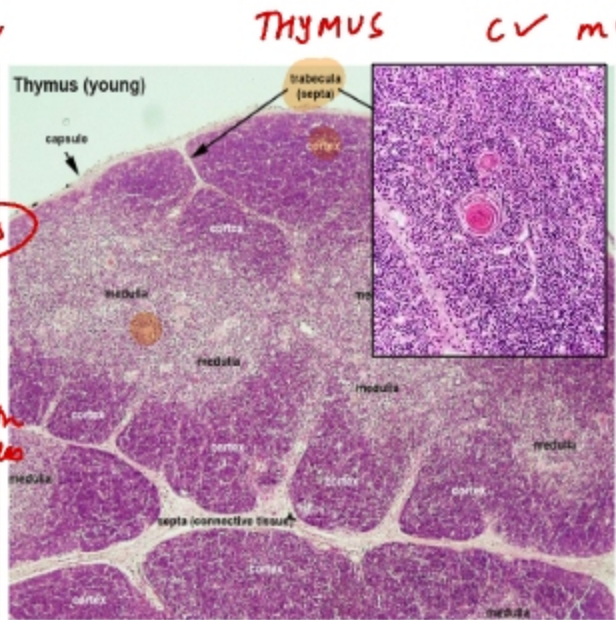


corpora amylacea  
prostate FT

# Lymphoid organs:

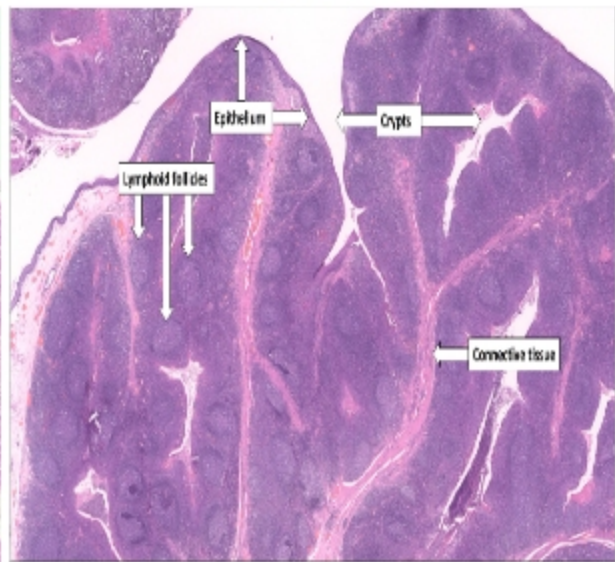


LN



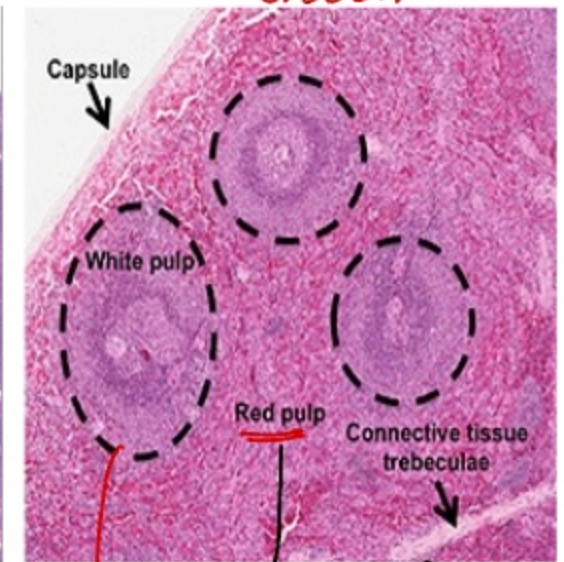
THYMUS cv mv

Hassall's corpuscles

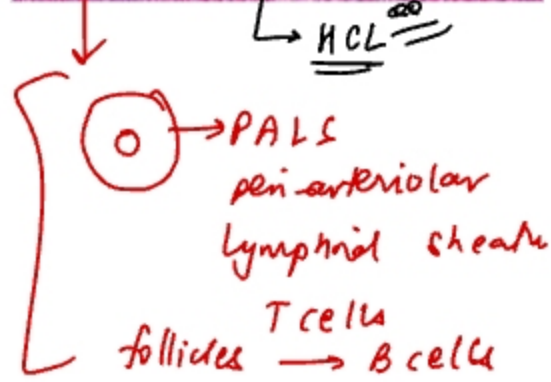


TONSILS

Stratified squamous

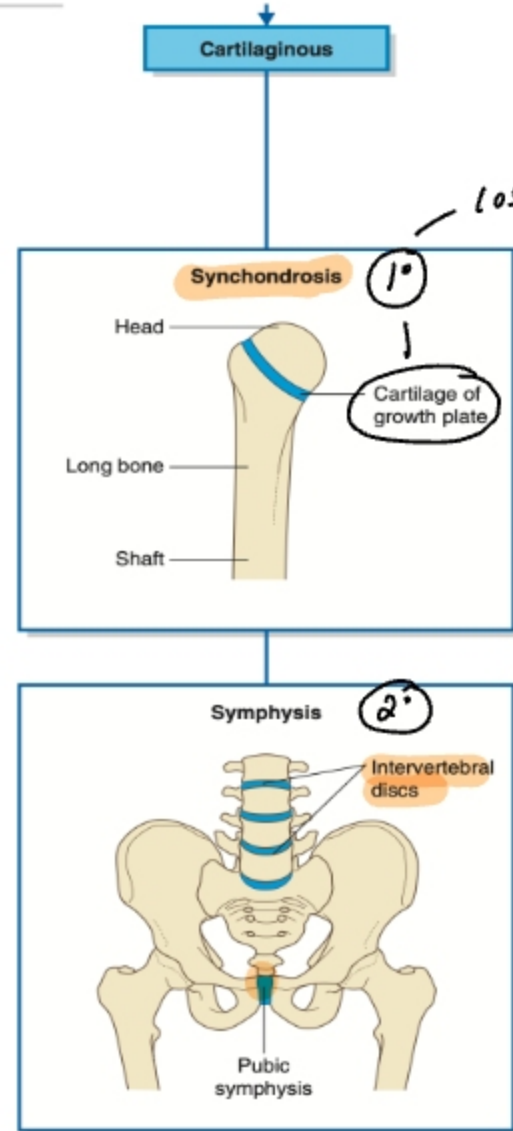
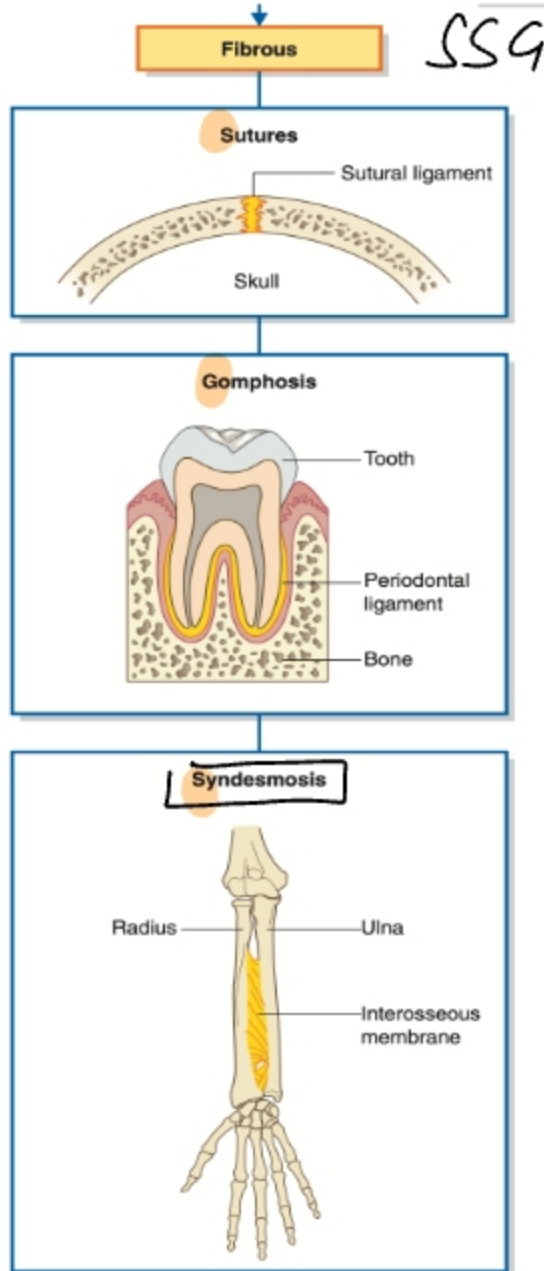
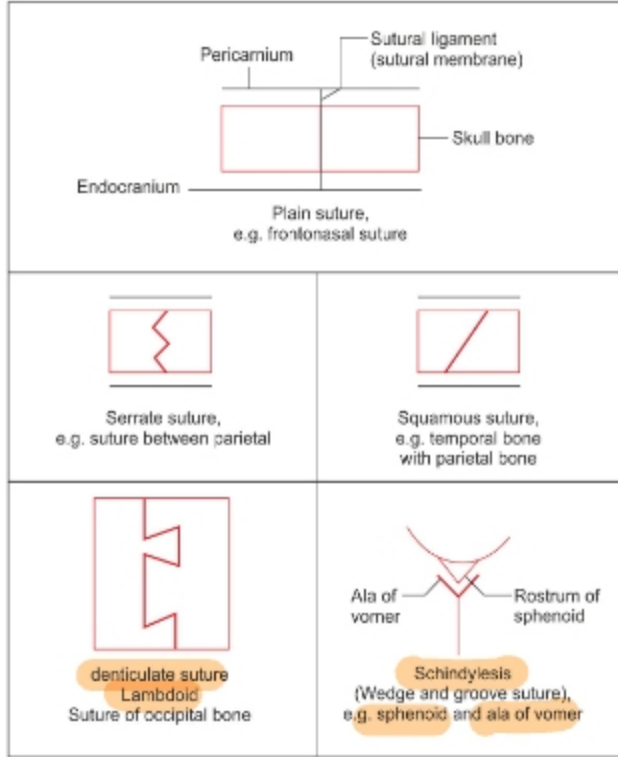


SPLEEN

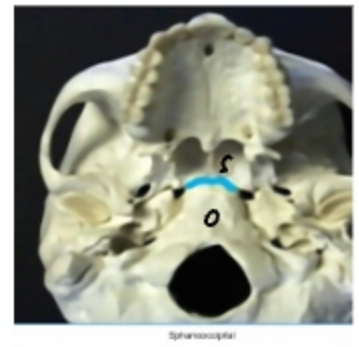

White pulp

# SOLID JOINTS



Costo-chondral jn



spheno-occipital

- Manubriosternal joint
- Xiphisternal joint
- Intervertebral disc
- Pubic symphysis
- Sacro-coccygeal joint

- Middle radio-ulnar joint
- Inferior tibio-fibular joint
- Sacroiliac joint

Contact admin  
Join our group

# JOINTS-SYNOVIAL

Ball & socket

- ✓ Incus-stapes
- Hip I-S
- Shoulder
- ✓ Talo-calcaneo-navicular T-C-N

Saddle

- ✓ Malleus-incus M-I
- 1st CMC
- ✓ Calcaneo-cuboid
- Sterno-clavicular
- Femur-patella

Ellipsoid

- ✓ Atlanto-occipital YES
- Sup/inf radio-ulnar

Pivot

- ✓ Atlanto-axial NO
- Wrist MCP/MTP

Condylar

- TMJ
- Knee

Hinge

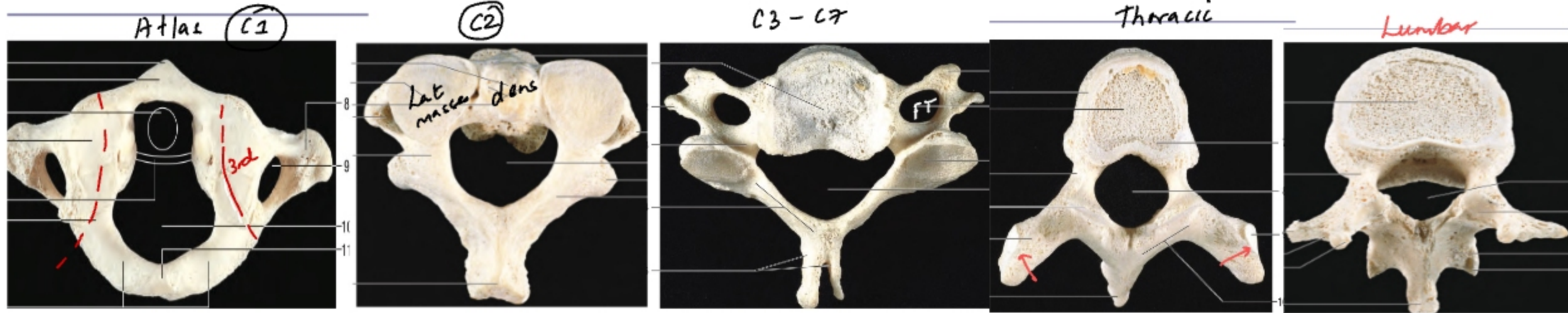
- Ankle
- Elbow
- IP

Plane

- ✓ Intercarpal
- ✓ Intertarsal
- ✓ Sup tibio-fibular
- ✓ Acromio-clavicular
- Costo-transverse
- Costo-vertebral
- Sterno-costal except 1st

↓  
Fibrous jt

# MISCELLANEOUS



Normal prostate volume: 20ml

Reticular fibres absent in: thymus

Superficial posterior compartment of leg: lacks neurovascular bundle

CCA division at the level of: C4 "bifurcation" - T4 / L4

Transverse facial artery: STA

Primary ossification centres appear before birth and are single EXCEPT: clavicle (2)  
→ except carpals

Only long bone with membranous ossification/ first to start ossification (5<sup>th</sup> week POG): clavicle  
→ calvarial / facial  
(last)

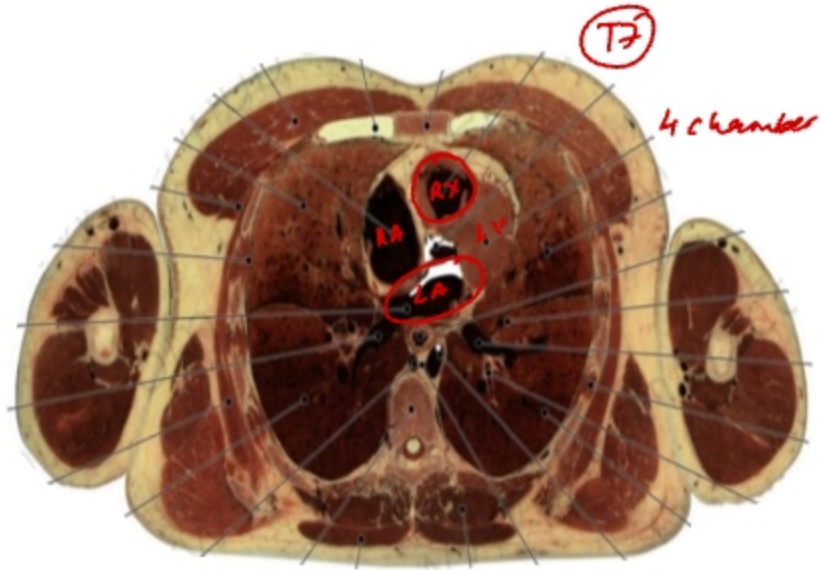
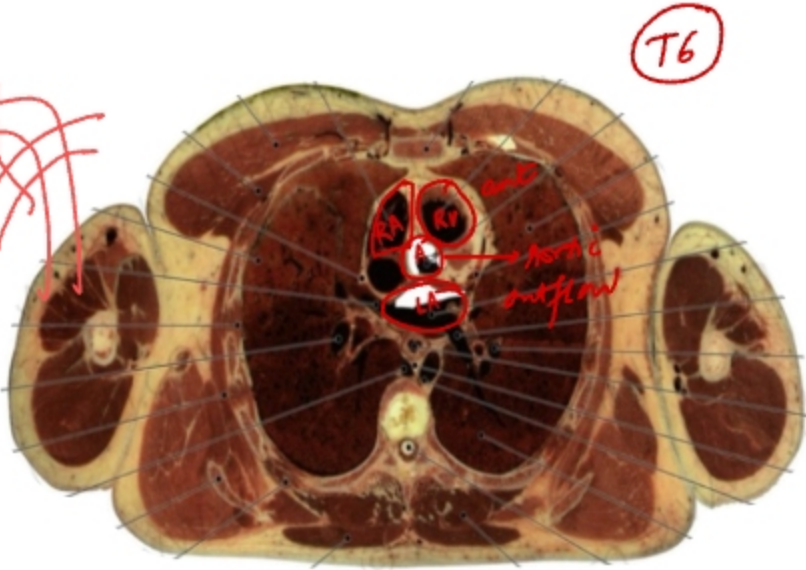
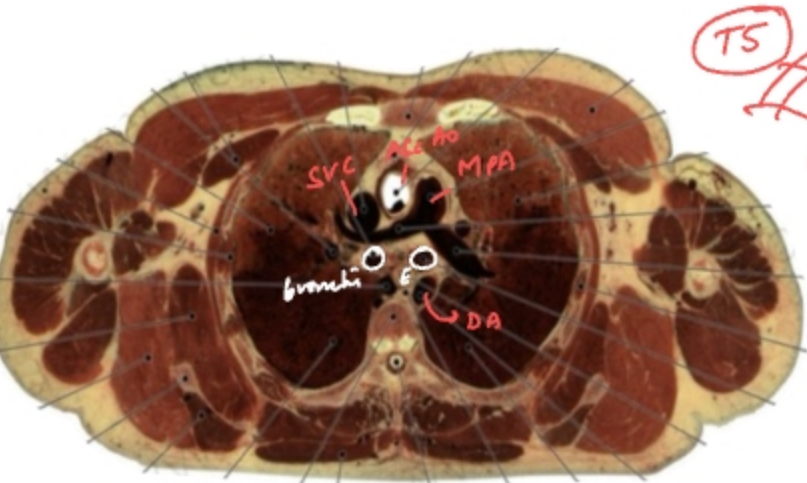
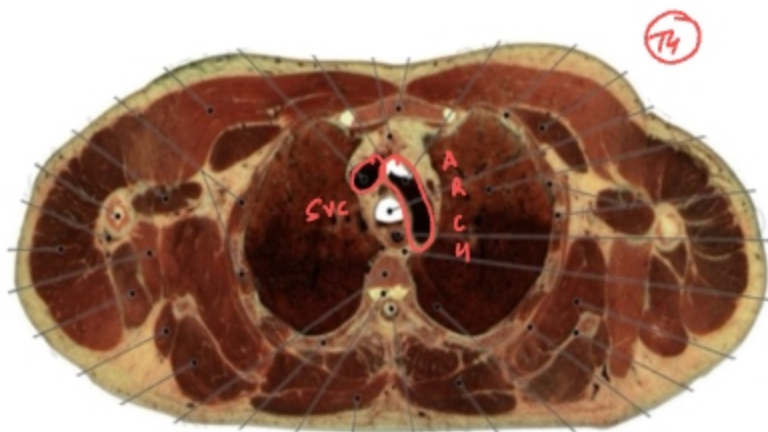
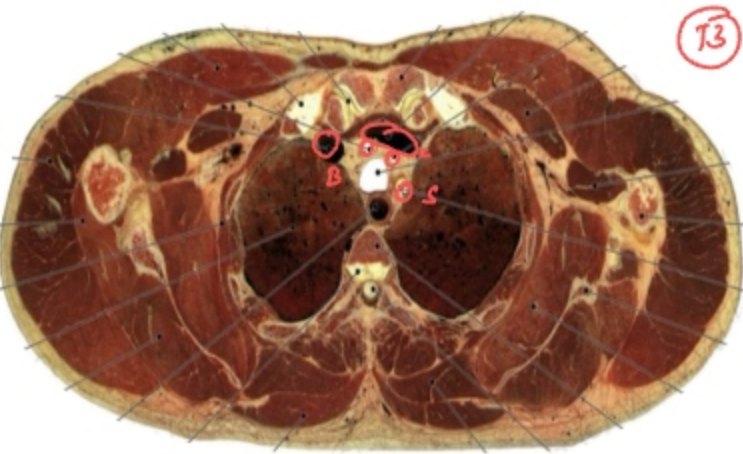
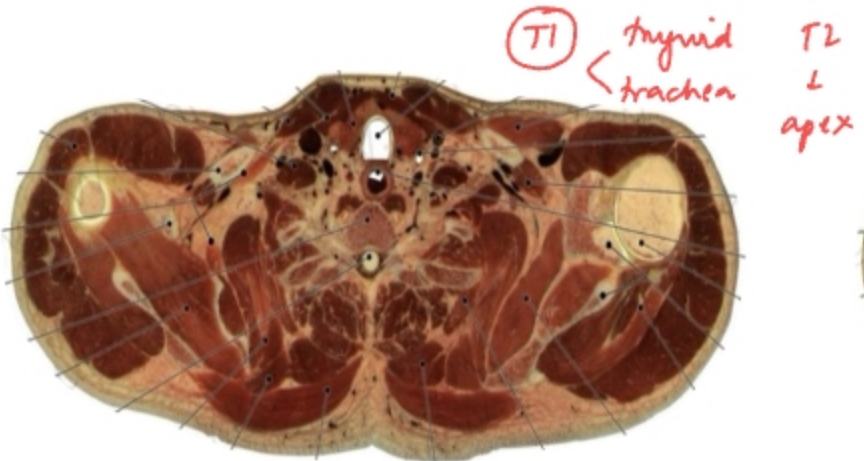
25 cm: Esophagus - Duodenum - Ureter - Descending colon

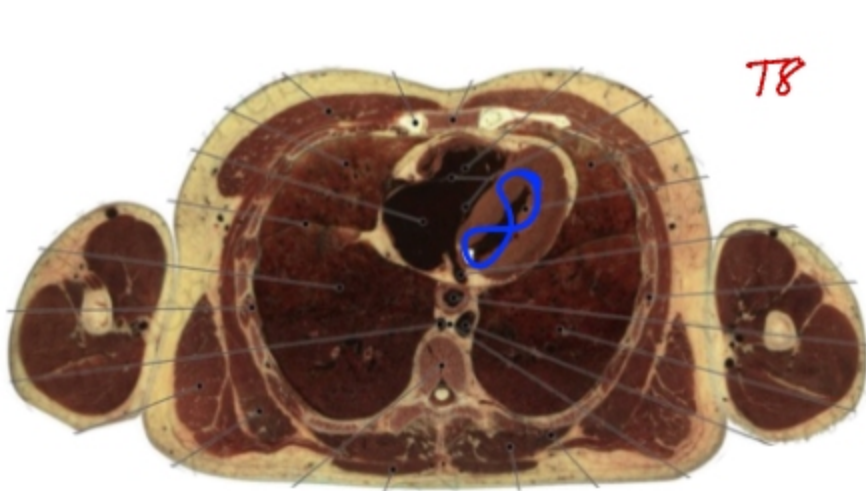
45 cm: Spinal cord - Thoracic duct - Vas deferens - Sartorius - Femur - Transverse colon

<b>Composite muscle</b>	<b>Nerve supply</b>
<b>Digastric</b>	Anterior belly: V3 Posterior belly: Facial nerve
<b><u>Flexor digitorum profundus</u></b>	Medial half: Ulnar nerve Lateral half: Anterior interosseous (branch of median nerve)
<b><u>Adductor magnus</u></b>	Adductor part: Obturator nerve Hamstring part: Tibial nerve
<b><u>Biceps femoris</u></b>	Long head: Tibial nerve Short head: Common peroneal nerve
<b><u>Pectineus</u></b>	Anterior fibres: Femoral nerve Posterior fibres: Obturator nerve
<b>Brachialis</b>	Proprioceptive: Radial nerve Motor: Musculocutaneous
<b><u>Flexor pollicis brevis</u></b>	Superficial head: Median nerve Deep head: Deep branch of ulnar nerve
<b>Pectoralis major and minor</b>	Medial and lateral pectoral nerves
<b>Subscapularis</b>	Upper and lower subscapsular nerves

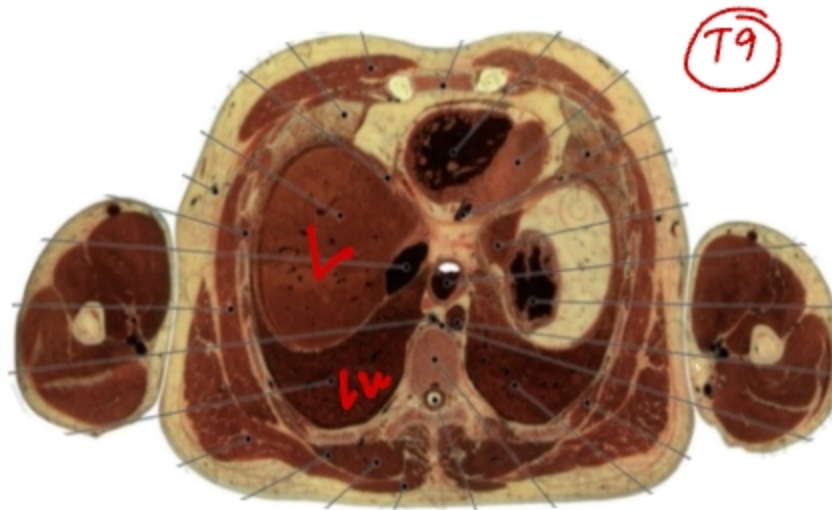
**Parallel arrangement: Thyrohyoid, Sternohyoid, Rectus abdominis, Fusiform: Biceps brachii, digastric**

# Cadaveric sections

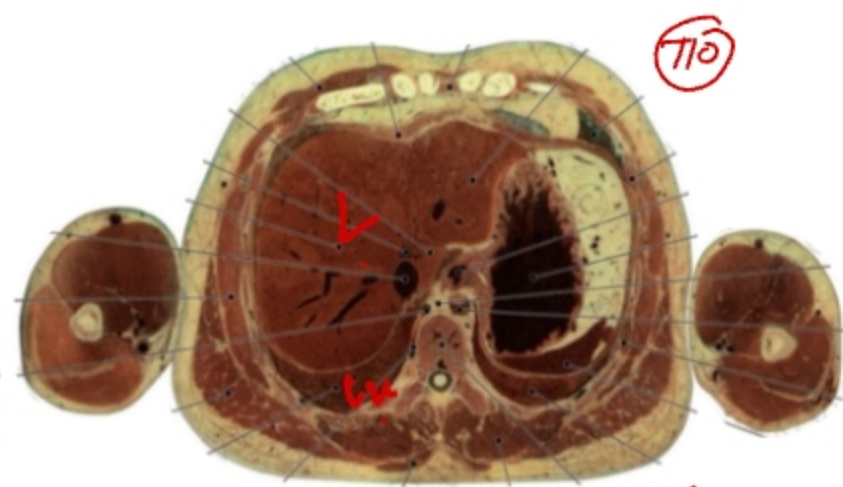




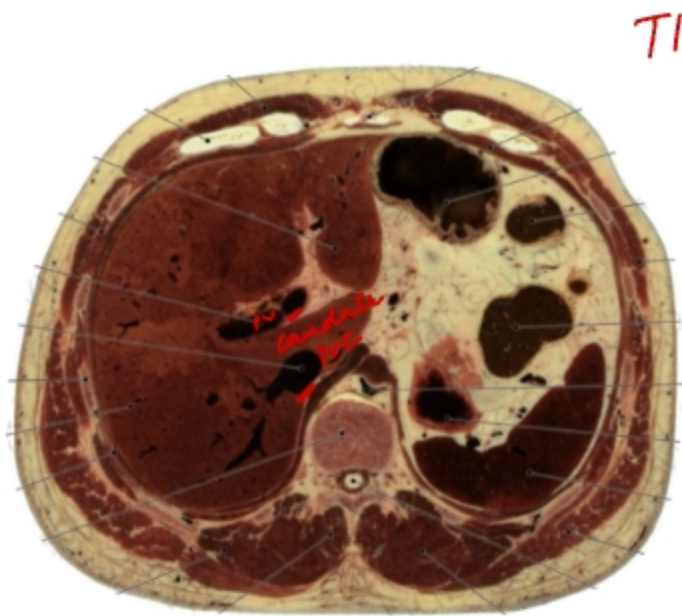
T8



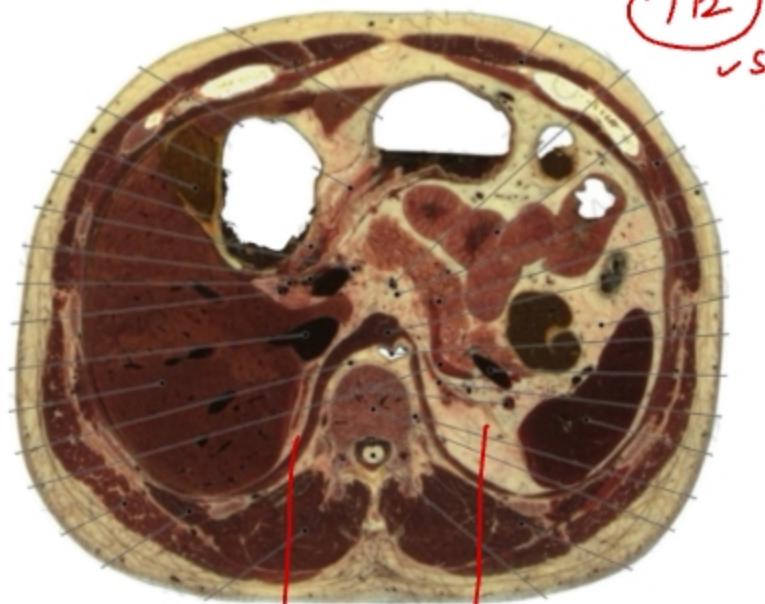
T9



T10

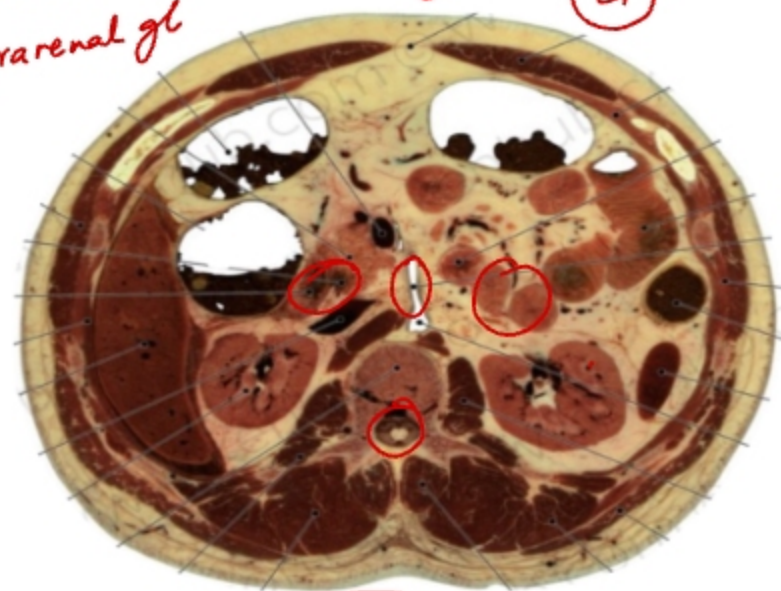


T11



T12

✓ sc  
✓ suprarenal gl



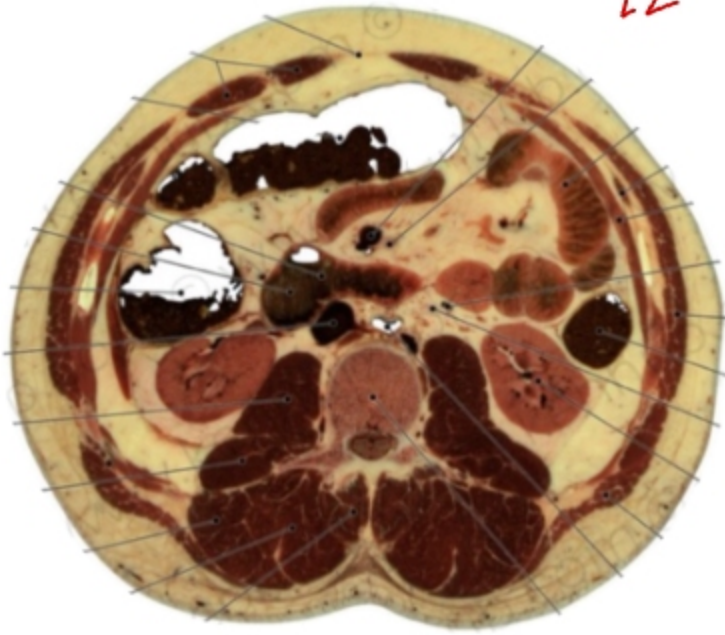
✓ sc ✓  
L1

Rt: pyramidal

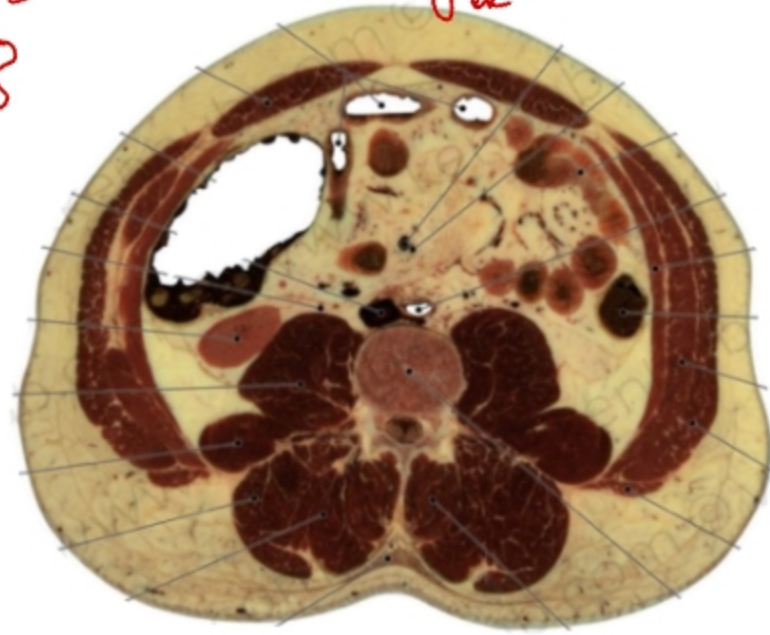
Lt: semilunar

transpyloric

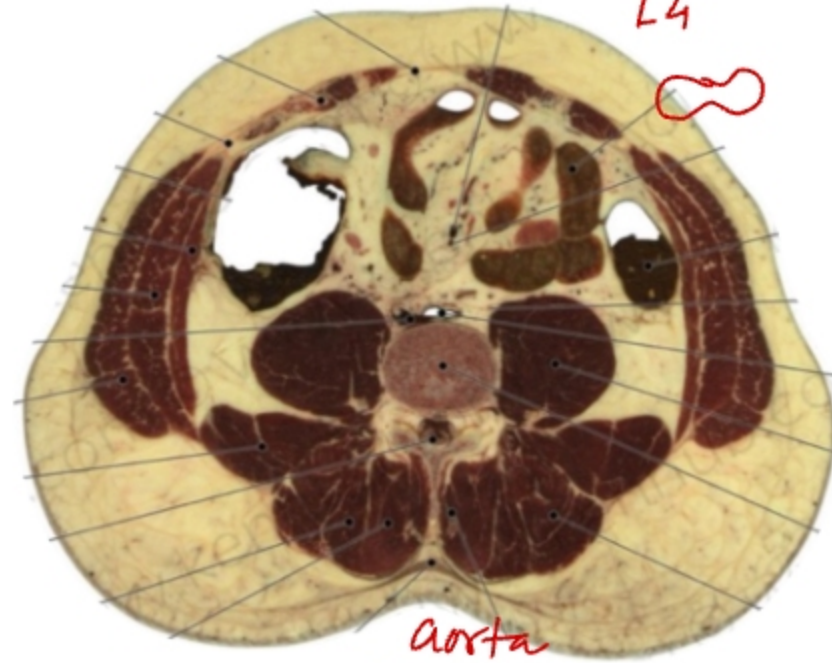
- fundus GB
- SMA
- D1 - D4 (DJ flexure)



L2 x SC  
✓ B



L3 P W



L4

aorta

L5 - IVC bifurcates

T1  
T2  
T3 BCS ✓  
T4 arch ✓  
T5  
T6 LVOT - Ao  
T7 4  
T8 ♥

T9  
T10 =  
T11 =/  
T12 ✓ SC x B  
L1 ✓ SC ✓ B  
L2 x SC ✓ B  
L3 B  
L4 O O  
L5 O O